

Direct and Indirect Diaphragmatic Bullet-Induced Lacerations with a Very Minor Injury to the Lung

Hamdy Dosoky Elayouty^{1,2*}, Mohamed Sami Hamed¹, Ahmed Hamdy Elayouty^{1,2}

¹Department of Cardio-Thoracic Surgery, Suez Canal University, Ismailia, Egypt

²Khalifa Hospital for Fine Surgeries and Emergency, Ismailia, Egypt

Email: *h.dosoky@yahoo.com, Mohsamy1987@gmail.com, dr.ahmedelayouty@yahoo.com

How to cite this paper: Elayouty, H.D., Hamed, M.S. and Elayouty, A.H. (2025) Direct and Indirect Diaphragmatic Bullet-Induced Lacerations with a Very Minor Injury to the Lung. *Open Journal of Thoracic Surgery*, 15, 27-35.

<https://doi.org/10.4236/ojts.2025.153003>

Received: August 10, 2025

Accepted: September 13, 2025

Published: September 16, 2025

Copyright © 2025 by author(s) and Scientific Research Publishing Inc. This work is licensed under the Creative Commons Attribution International License (CC BY 4.0).

<http://creativecommons.org/licenses/by/4.0/>



Open Access

Abstract

Purpose: Diaphragmatic injuries are relatively rare and result from either blunt or penetrating trauma. We reported a bullet that resulted in two separate diaphragmatic lacerations and hernias: One by the penetrating bullet and the second by the associating blunt trauma. **Observations:** A 23 years old young man who sustained a bullet injury resulting in isolated diaphragmatic lacerations with minor lung impact. The diaphragmatic injuries resulted in omental herniations. Symptoms of diaphragmatic injuries were masked by associated injuries and missed in the Primary Care Unit. After referring the patient to our Unit in Abo-khalifa Hospital for Emergency and Fine Surgeries because of upper abdominal discomfort, computerized tomography showed two diaphragmatic tears and the herniated omentum. A lateral small tear in line with the inlet and exit of the bullet and adjacent to the minor lung lesion can be explained by direct bullet injury. The second larger medial radial diaphragmatic tear can be due to indirect trauma caused by markedly increased intrathoracic pressure with closed epiglottis; this pressure was immediately created on penetration of skin. This increasing pressure is going to be relieved by either bronchial or diaphragmatic rupture. Thoracoscopy confirmed the diagnosis and assisted complete management. Smooth reduction of the hernias, closure of the diaphragmatic defects and application of one clip onto the lung lesion. **Conclusions:** High suspicion of diaphragmatic injuries helps early diagnosis of these rare traumatic lesions. Computerized tomography of the chest with barium meal has a high sensitivity and specificity for diagnosis of traumatic diaphragmatic hernias. Uniporter thoracoscopy is a good safe diagnostic and therapeutic tool for traumatic diaphragmatic lacerations with hernias.

Keywords

Bullet Injuries to the Diaphragm, Omental Herniation through Holes in Diaphragm, Thoracoscopic Management of Rupture Diaphragm, Diagnosis of Penetrating Diaphragmatic Injuries, Direct and Indirect Diaphragmatic Simultaneous Injuries

1. Introduction

Missed diaphragmatic injuries can result in major morbidity and/or mortality. Penetrating thoracoabdominal injuries carry a high risk of diaphragmatic injuries but can also pose a diagnostic dilemma due to their small size and the frequent lack of an associated hernia. Penetrating injury to the abdomen or chest from the 4th through the 12th thoracic dermatomes anteriorly and the 3rd lumbar region posteriorly. Probability of diaphragmatic injury was higher among patients with penetrating injury to the 8th intercostal space. Thus, surgeons should consider the bullet to have potentially caused a diaphragmatic injury. This role makes it easy to predict diaphragmatic injury in suspected cases [1].

Diaphragmatic injuries can result in significant ventilatory compromise. Diagnosis may not be obvious [2]. It is made preoperatively in only 40% - 50% of left-sided and 0% - 10% of right-sided blunt diaphragmatic ruptures [3]. In 10% - 50% of patients, diagnosis is not made in the first 24 hours. In only approximately 3% of cases, the injury is bilateral [4]. Early deaths usually result from associated injuries rather than the diaphragmatic tears. Mortality ranges from 5% to 30% [5].

If one gets shot in the diaphragm, and if the diaphragm is injured, it is an indication that more severe injuries to organs may have occurred. Thus, the mortality after a diagnosis of diaphragmatic rupture is 17%, with most deaths due to associated lesions. In our presented case, the diaphragm suffered two lacerations with minimal lung basal lesion [6].

Chest X-ray remains an important tool in early diagnosis but primarily relies on the presence of a hernia or a discontinuity of the diaphragm, which is not typically seen with penetrating injuries. Computed tomography has a higher sensitivity and specificity and improves preoperative diagnosis. Organ herniation was observed significantly more often in blunt trauma than in penetrating trauma [7].

The surgical procedure involved a reduction of herniated viscera and a suture of the diaphragm by non-absorbable suture materials in 85% [8].

Thoracoscopy and/or laparoscopy provide the most definitive morphological assessment of the diaphragm [9]. One prospective study, in which patients suffering penetrating trauma to the left lower chest underwent routine laparoscopy, found that 24% had sustained occult diaphragmatic injuries [10]. These techniques can also identify other injuries to viscera which might otherwise not be apparent in radiological imaging [11].

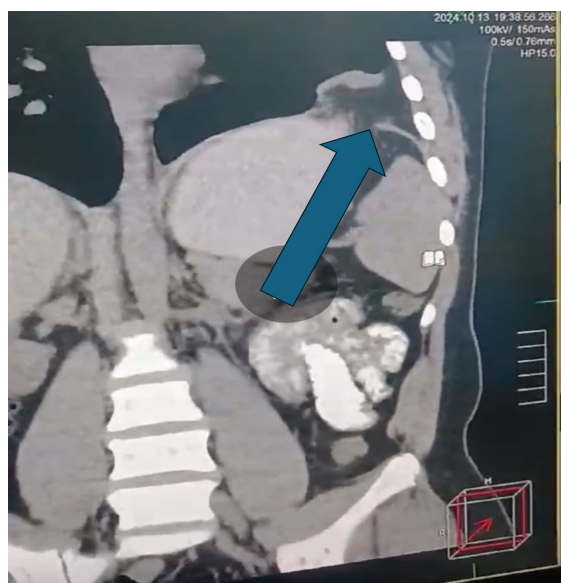
Definitive treatment of diaphragmatic injury requires surgical repair, the ap-

proach (trans-abdominal or trans-thoracic) being determined by co-existing injuries. The trans-abdominal approach is otherwise preferred in the acute setting [12]. In patients undergoing laparotomy for other injuries, the hemidiaphragms should be visualized to identify any tears [13].

According to McDonald, *et al.*, 2018, guidelines: In left-sided thoracoabdominal stab wound patients who are hemodynamically stable and without peritonitis, should laparoscopy be performed to decrease the incidence of missed diaphragmatic injury [13].

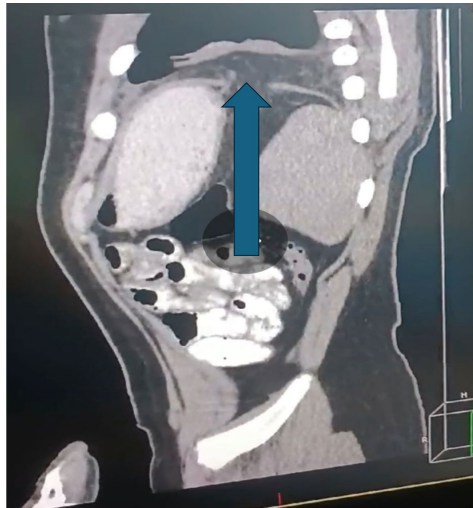
2. The Case Presentation

We present a case of a male adult patient, 23 years old. He came from Aswan to Ismailia 2 weeks after a bullet injury to his left side of chest. The inlet of the bullet was through the left nipple, and the exit was just below the angle of his left scapula. We expected severe pulmonary and/or gastric injuries. Diagnosis of diaphragmatic tears without the presence of herniated viscera remains difficult and a high index of suspicion must be maintained. Chest CT showed two interruptions in the left diaphragmatic cupula with omental herniations through both. This was confirmed with chest CT and barium swallow contrast (Figure 1, Figure 2). Physical examination showed mild upper abdominal tenderness. The abdominal ultrasound examination did not show any evidence of intra-abdominal visceral injury. CT of chest with oral contrast showed the lateral hole with herniated omental fat. This smaller antero-lateral diaphragmatic tear is nearer to the exit of the bullet (Figure 1), the medial larger tear with herniated omental fat lies postero-medial and is radially directed diaphragmatic tear (Figure 2).



The Arrow points to the smaller antero-lateral diaphragmatic tear. It is nearer to the exit of the bullet.

Figure 1. CT of chest with oral contrast showing the lateral hole with herniated omental fat.



The Blue Arrow points to the larger postero-medial diaphragmatic tear. It is radial in direction.

Figure 2. CT of chest with oral contrast showing the larger medial radial tear with herniated omental fat.

Once diagnosed, the only treatment for a diaphragmatic tear was a decision of surgery. As our patient was hemodynamically stable and according to the guidelines, we got an informed consent to proceed with thoracoscopy. It was done using a thin tube with a tiny video camera at the end (thoracoscope). It's a type of minimally invasive surgery. We made three cuts, each one was smaller than half an inch over the seventh, sixth and fourth ribs., put a thoracoscope into the pleural space and put other tools into the other incisions.

Thoracoscopic exploration, single lung ventilation and CO₂ insufflation were performed. The latter facilitated reduction of herniated omental fat and closure of the smaller defect followed by reduction and closure of the larger medial one. There were adhesions between omental fat and edges of the holes as well as the base of the lung (**Figure 3, Figure 4**). Adhesions were released with blunt dissection. We found a small posterior basal lung burn with a small blood clot covering that area. The defects were repaired in two layers with non-absorbable suture materials. Inserted chest tube and closed chest wall in layers. One day after thoracoscopy, plain x-ray of chest showed gas under the diaphragm (**Figure 5**). During thoracoscopy, we insufflated CO₂ gas that facilitated reduction of the herniated omentum, some gas escaped under the diaphragm.

Young age and good preparation enhanced early recovery, and the patient was discharged on the 4th postoperative day. One month later, it did not show any complications.

3. Discussion

Penetrating stab wounds are particularly dangerous as small defects in the diaphragm contribute to missed diagnosis and increased risk of gastric or intestinal strangulation. Signs to look for include absence or displacement of fundic gas,

elevation of the hemidiaphragm, blunting of the diaphragmatic angle and hemo-pneumothorax.



Figure 3. Antero-lateral hole of the diaphragm after reduction of herniated omental fat.

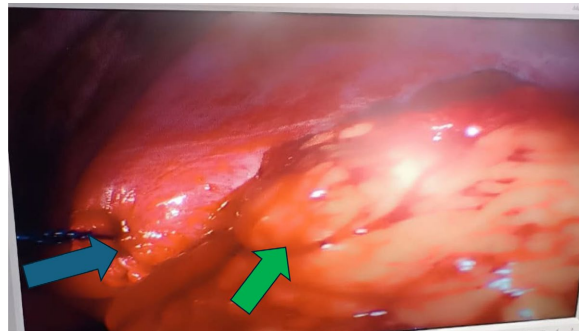
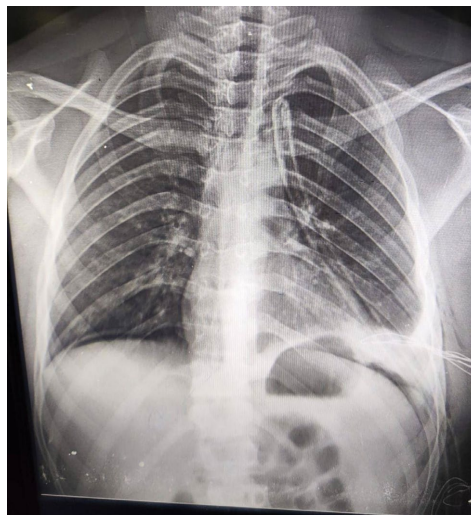

Figure 4. The smaller hole of diaphragm has been closed (The blue arrow). The other tear and the herniated omental fat lie (The green arrow), postero-medial to the repaired antero-lateral laceration (tear).



During thoracoscopy, we insufflated CO₂ gas that facilitated reduction of the herniated omentum, some gas escaped under the diaphragm.

Figure 5. One day after thoracoscopy, plain x-ray of chest showed: (gas under the diaphragm).

Injuries to the diaphragm occur in 3% to 5% of patients who sustain penetrating chest trauma and are associated with an increased risk of major morbidity and mortality. Diaphragmatic injuries can be difficult to diagnose and, when missed, can result in a chronic diaphragmatic hernia, with the potential for incarceration, strangulation, and death. Video-assisted thoracoscopic surgery (VATS) has been shown to improve the sensitivity, specificity, and accuracy of identifying such lesions. The diagnosis in our case was missed at the primary care unit. CT-Chat proved the presence of not only one but also another larger radially directed tear.

This unique case presentation describes the first case of a penetrating bullet that only causes two diaphragmatic tears with omental herniation. Knowledge of the mechanisms that produce diaphragmatic rupture combined with information regarding the victim's seat position and direction of the impacting force should lead to a high index of clinical suspicion for this lesion after blunt trauma. Due to the pressure differential between abdomen and thorax, the natural history of these injuries is one of enlargement and herniation. A sudden increase in the pressure gradient between the plural and peritoneal cavities that occur with high-speed blunt or penetrating trauma will lead to disruptions of the diaphragm and diaphragmatic tears [14].

In this unique case presentation, we found a lateral small tear in line with the inlet and exit of the bullet and adjacent to the minor lung lesion, this diaphragmatic laceration can be explained by direct bullet injury. The second larger medial radially directed-diaphragmatic tear can be due to indirect trauma caused by the markedly increased intrathoracic pressure with closed epiglottis; this pressure was immediately created on penetration of skin and induced by intense pain or fear. His cousin was shooting him under his vision, face to face. This increasing intrathoracic pressure is going to be relieved by either bronchial or diaphragmatic rupture (a form of severe barotrauma). The diaphragm ruptured due to indirect trauma producing that large medial radially directed laceration followed by direct diaphragmatic injury in the path of the bullet. Diaphragmatic injury is a recognized consequence of high velocity blunt or penetrating trauma to the abdomen and/or chest [15].

The traumatic diaphragmatic hernia was missed but shortly detected in our Center. Diagnosis of diaphragmatic rupture following thoracic penetrating trauma is very challenging in asymptomatic patients with stable vital signs. Diaphragmatic injury is easily missed as it is uncommonly encountered and may not cause respiratory or gastrointestinal symptoms in the acute phase. Diaphragmatic injury has an associated mortality as high as 25% and failure to intervene can lead to delayed complications, e.g. bowel obstruction, perforation, and intra-thoracic sepsis [16].

Assessment with sonography is significant.: Sensitivity 50%, specificity 100%, positive and negative predictive values: 9.1% (95% CI: 1.5 - 30.6), Infinity, and 0.1 (95% CI: 0.02 - 0.37), respectively. The overall accuracy of assessment with sonography in this regard was 75.0% (95% CI: 42.3 - 100.0). It was not conclusive in our

case. It cannot be the definitive alternative to diagnostic laparoscopy or thoracoscopy to detect diaphragm rupture.

CT-chest is more accurate in diagnosis of diaphragmatic injuries. Various studies have revealed CT-chest to have a variable sensitivity and specificity of 61% - 87% and 72% - 100%, respectively, for the diagnosis of diaphragmatic rupture. The dangling diaphragm sign denotes that a part of the diaphragm appears folded, thickened, and hanging.

The most definitive diagnostic approach can be thoracoscopy or laparoscopy as proved by several studies. There are reported different approaches for surgical treatment: abdominal or thoracic, traditional incision or minimally invasive approaches. Repair was done using absorbable or nonabsorbable suture material, interrupted or continuous and in one or two layers. The most important fact is that any tear should be closed whatever its size.

Postoperative Follow up for 4 weeks is significant to exclude development of any complications. Clinical and radiological examinations are indicated during follow up. Other authors reported the morbidity rate was 10 % and mortality rate 5%. The presented case had no morbidity, and the patient is having a good eventless life.

4. Conclusions

The importance of early diagnosis of diaphragmatic tears in reducing mortality, morbidity and hospital stay is significant. A high index of suspicion, careful clinical examination, and serial chest radiographs remain the best way of making the diagnosis. Thoracoscopy is a good approach for diagnosis and treatment.

A penetrating bullet can produce diaphragmatic lacerations both directly and indirectly.

Ethical Approval

Written informed consent was obtained from the patient for publication of this case report and accompanying images. A copy of the written consent is available and can be submitted to any reasonable request.

Author Contributions

Ahmed Hamdy initiated the report which was drafted by Hamdy D. Elayouty. All authors made important critical revisions. All authors approved the final manuscript.

Conflicts of Interest

The authors declare that they have no competing interests.

References

- [1] Mahamid, A., Peleg, K., Givon, A., Alfici, R., Olsha, O. and Ashkenazi, I. (2017) Blunt Traumatic Diaphragmatic Injury: A Diagnostic Enigma with Potential Surgical Pitfalls. *The American Journal of Emergency Medicine*, **35**, 214-217.

- <https://doi.org/10.1016/j.ajem.2016.10.046>
- [2] Abdellatif, W., Chow, B., Hamid, S., Khorshed, D., Khosa, F., Nicolaou, S., *et al.* (2020) Unravelling the Mysteries of Traumatic Diaphragmatic Injury: An Up-To-Date Review. *Canadian Association of Radiologists Journal*, **71**, 313-321. <https://doi.org/10.1177/0846537120905133>
- [3] Thiam, O., Konate, I., Gueye, M.L., Toure, A.O., Seck, M., Cisse, M., *et al.* (2016) Traumatic Diaphragmatic Injuries: Epidemiological, Diagnostic and Therapeutic Aspects. *SpringerPlus*, **5**, Article No. 1614. <https://doi.org/10.1186/s40064-016-3291-1>
- [4] Morito, A., Nakagawa, S., Imai, K., Uemura, N., Okabe, H., Hayashi, H., *et al.* (2021) Successful Surgical Rescue of Delayed Onset Diaphragmatic Hernia Following Radiofrequency Ablation Using a Thoracoscopic Approach for Hepatocellular Carcinoma: A Case Report. *Surgical Case Reports*, **7**, Article No. 130. <https://doi.org/10.1186/s40792-021-01213-8>
- [5] Uzzaman, M., Nair, M., Al-Zuhir, N., Jadeja, A. and Navaratnam, R. (2011) Changing Trends in the Pattern and Outcome of Stab Injuries at a North London Hospital. *Journal of Emergencies, Trauma, and Shock*, **4**, 455-460. <https://doi.org/10.4103/0974-2700.86628>
- [6] Williams, M., Carlin, A.M., Tyburski, J.G., Blocksom, J.M., Harvey, E.H., Steffes, C.P., *et al.* (2004) Predictors of Mortality in Patients with Traumatic Diaphragmatic Rupture and Associated Thoracic And/or Abdominal Injuries. *The American Surgeon*, **70**, 157-163. <https://doi.org/10.1177/000313480407000212>
- [7] Petrone, P., Leppäniemi, A., Inaba, K., Søreide, K. and Asensio, J.A. (2007) Diaphragmatic Injuries: Challenges in the Diagnosis and Management. *Trauma*, **9**, 227-236. <https://doi.org/10.1177/1460408607087716>
- [8] Desser, T.S., Edwards, B., Hunt, S., Rosenberg, J., Purtill, M.A. and Jeffrey, R.B. (2009) The Dangling Diaphragm Sign: Sensitivity and Comparison with Existing CT Signs of Blunt Traumatic Diaphragmatic Rupture. *Emergency Radiology*, **17**, 37-44. <https://doi.org/10.1007/s10140-009-0819-5>
- [9] Leppäniemi, A. and Haapiainen, R. (2003) Diagnostic Laparoscopy in Abdominal Stab Wounds: A Prospective, Randomized Study. *The Journal of Trauma: Injury, Infection, and Critical Care*, **55**, 636-645. <https://doi.org/10.1097/01.ta.0000063000.05274.a4>
- [10] Simpson, J., Lobo, D. and Shah, A.B. (2000) Traumatic Diaphragmatic Rupture: Associated Injuries and Outcome. *Annals of the Royal College of Surgeons of England*, **82**, 97-100.
- [11] Hanna, W.C., Ferri, L.E., Fata, P., Razek, T. and Mulder, D.S. (2008) The Current Status of Traumatic Diaphragmatic Injury: Lessons Learned from 105 Patients over 13 Years. *The Annals of Thoracic Surgery*, **85**, 1044-1048. <https://doi.org/10.1016/j.athoracsur.2007.10.084>
- [12] Iadicola, D., Branca, M., Lupo, M., Grutta, E.M., Mandalà, S., Cocorullo, G., *et al.* (2019) Double Traumatic Diaphragmatic Injury: A Case Report. *International Journal of Surgery Case Reports*, **61**, 82-85. <https://doi.org/10.1016/j.ijscr.2019.07.030>
- [13] McDonald, A.A., Robinson, B.R.H., Alarcon, L., Bosarge, P.L., Dorion, H., Haut, E.R., *et al.* (2018) Evaluation and Management of Traumatic Diaphragmatic Injuries: A Practice Management Guideline from the Eastern Association for the Surgery of Trauma. *Journal of Trauma and Acute Care Surgery*, **85**, 198-207. <https://doi.org/10.1097/ta.0000000000001924>
- [14] Karmy-Jones, R. and Jurkovich, G.J. (2004) Blunt Chest Trauma. *Current Problems in Surgery*, **41**, 223-380. <https://doi.org/10.1016/j.cpsurg.2003.12.004>

- [15] Blaivas, M., Brannam, L., Hawkins, M., Lyon, M. and Sriram, K. (2004) Bedside Emergency Ultrasonographic Diagnosis of Diaphragmatic Rupture in Blunt Abdominal Trauma. *The American Journal of Emergency Medicine*, **22**, 601-604.
<https://doi.org/10.1016/j.ajem.2004.08.015>
- [16] Rossetti, G., Bruscianno, L., Maffettone, V., Napolitano, V., Sciaudone, G., Del Genio, G., *et al.* (2005) Giant Right Post-Traumatic Diaphragmatic Hernia: Laparoscopic Repair without a Mesh. *Chirurgia Italiana*, **57**, 243-246.