

# Introducing the Integrated Clinical fMRI Paradigm

Byron Bernal<sup>1,2</sup>, Magno R. Guillen<sup>1</sup>, Nolan Altman<sup>1,2</sup>, Santiago Medina<sup>1,2</sup>

<sup>1</sup>Department of Radiology, Nicklaus Children's Hospital, Miami, USA

<sup>2</sup>Herbert Wertheim College of Medicine, Florida International University, Miami, USA

Email: magno.guillen@nicklaushealth.org

**How to cite this paper:** Bernal, B., Guillen, M.R., Altman, N. and Medina, S. (2026) Introducing the Integrated Clinical fMRI Paradigm. *Open Journal of Radiology*, 16, 109-117.

<https://doi.org/10.4236/ojrad.2026.162012>

**Received:** December 22, 2025

**Accepted:** April 25, 2026

**Published:** April 28, 2026

Copyright © 2026 by author(s) and Scientific Research Publishing Inc.

This work is licensed under the Creative Commons Attribution International License (CC BY 4.0).

<http://creativecommons.org/licenses/by/4.0/>



Open Access

## Abstract

This study introduces and evaluates the “Integrated Functional Mapping” (IFM) clinical fMRI paradigm, a streamlined five-minute sequence designed to concurrently map language, bilateral motor, and visual cortical functions in pediatric patients undergoing presurgical evaluation for epilepsy. Methods: A cohort of 118 children aged 7 - 18 years (mean age 12.8) was scanned between 2018 and 2023 using a Philips Ingenia 1.5 T system. The IFM paradigm incorporated four tasks—semantic decision (words vs. tones), right- and left-hand motor responses, and visual stimulation—within a single block design run modeled with multiple orthogonal regressors. Data processing utilizes FSL with custom scripts, applying standard preprocessing and thresholding protocols. Clinical validity was assessed using a comparator auditory description task (ADT) for language lateralization. Results: The IFM paradigm fully activated receptive and expressive language areas in 97.5% and 85.6% of patients, respectively, while motor and visual activations were achieved in 95.7% and 94.1% of cases. Language lateralization results from the IFM and ADT tasks demonstrated strong concordance (97.3% for receptive and 99% for expressive language). Additionally, IFM maps exhibited reduced noise and motion artifacts compared to conventional single-task paradigms. Conclusions: The IFM fMRI paradigm offers reliable, simultaneous mapping of critical functional domains within a concise five-minute acquisition. It is well-tolerated by pediatric patients, enhances data quality by minimizing motion artifacts, and significantly reduces overall clinical scanning time. This approach promises an efficient screening and planning tool for pediatric presurgical fMRI, particularly in scenarios where motion or time constraints limit the feasibility of multi-run protocols.

## Keywords

Functional MRI, Pediatric Epilepsy, Language Mapping, Motor Cortex,

---

## Visual Cortex, Multi-Regressor Paradigm, Pre-Surgical Planning, IFM Paradigm

---

### 1. Introduction

Functional Magnetic Resonance Imaging (fMRI) is currently a standard tool in the pre-surgical evaluation of patients who are candidates for brain surgery. The goal in these cases is to localize critical areas involved in expressive and receptive language, primary sensory-motor functions of each hand, and visual functions.

Alternative mapping techniques exist but are often invasive and difficult to implement in children. Young children may require up to five tasks to cover essential areas for surgical planning and counseling. Given that task-based fMRI runs typically last 3 - 6 minutes each, a complete clinical session may take 20 - 30 minutes, often extending to 40 minutes when setup, training, and repetition are required. In some cases, the entire procedure may last up to one hour due to various challenges, the most common of which is patient motion. Younger patients can typically cooperate for 5 - 10 minutes but maintaining a motionless posture for longer periods is difficult.

Therefore, a single technique capable of mapping motor, visual, and language functional areas simultaneously would be highly desirable.

Task-based clinical fMRI often employs a block design paradigm, in which one condition (A—probe) is contrasted with another (B—control). The subject alternates between conditions every few seconds (typically 20 - 40 s). The model is then defined mathematically by a function called a regressor. Accurate modeling requires orthogonalization to allow independent estimation of each condition's contribution to brain activity.

Based on these principles, we developed a block-design, multi-regressor paradigm that simultaneously tests expressive and receptive language, bilateral somatosensory-motor hand representation, and bilateral visual cortical areas. The entire task lasts only 5 minutes.

This paper reports our experience with a large group of pediatric patients who underwent this “Integrated Functional Mapping” (IFM) paradigm as part of their pre-surgical evaluation for epilepsy.

### 2. Procedures

All patients underwent fMRI as part of the standard clinical work-up for epilepsy surgery, under a specific request from an attending physician. A total of 118 patients were scanned using the IFM paradigm between 2018 and 2023. These cases also underwent a dedicated language-controlled task based on sentence comprehension. Among them, 104 were right-handed, 12 left-handed, and 2 were ambidextrous. Ages ranged from 7 to 18 years (mean age 12.8). All were native English speakers. All scans were performed on a Philips Ingenia 1.5 T (Netherlands) sys-

tem utilizing a 15-channel SENSE-enhanced parallel imaging head coil.

**Paradigm**

The IFM paradigm consisted of 150 volumes with TR = 2 s (total duration: 5 minutes). It included four intertwined tasks: a semantic decision task, two alternating motor tasks (right and left hands), and a visual task.

Patients held a small sponge in each hand and were instructed to fixate on a screen displaying two visual conditions:

Condition OFF—a black screen with a central fixation cross.

Condition ON—an animation of whirling circles.

No responses were required for this part of the task.

Simultaneously, auditory stimuli alternated between two conditions:

Condition OFF—pairs of tones (same or different).

Condition ON—pairs of words (synonyms or antonyms).

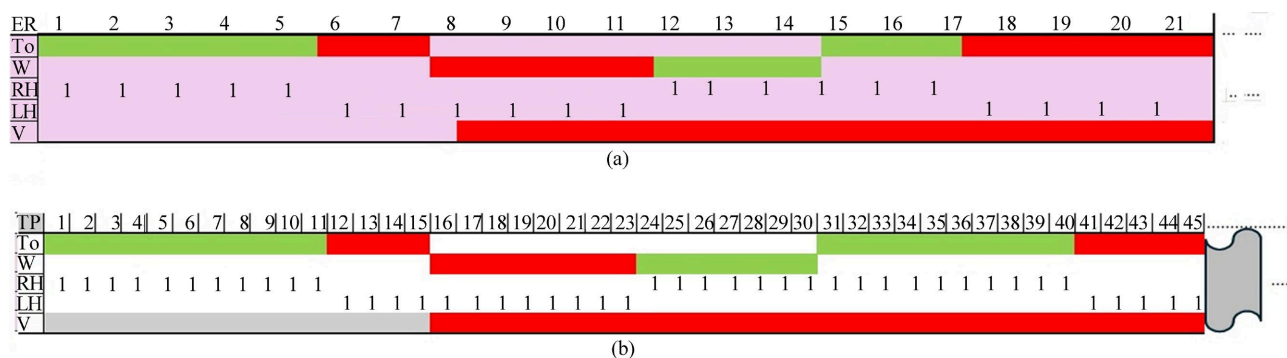
The ON condition for the auditory stimuli required semantic discrimination, a highly lateralized language function. Patients responded by squeezing the right sponge twice for “*same*” judgments (equal tones/synonyms) and the left sponge twice for “*different*” judgments (different tones/antonyms). Two additional regressors were computed to capture each hand’s motor responses:

Motor regressors (for each hand):

Condition OFF—no squeezing response (contralateral hand responding)

Condition ON—squeezing response (LH—*different*, RH—*same*)

These two conditions were counterbalanced, and stimuli were grouped into short blocks of similar types with variable lengths. In other words, responses for each hand were organized into blocks combining congruent (either similar or different) tones and words. A graphical depiction of the paradigm is shown in **Figure 1(a)**.



**Figure 1.** (a) IFM paradigm. Exemplary excerpt of the first 35 Event responses (ER). To: tones; W: words; RH: right hand; LH: left hand; V: visual. For To and W conditions, green indicates stimuli of the same category—either identical tones or synonyms—while red represents stimuli of different categories—distinct tones or antonyms—grouped to form epochs. Contrasts: To vs. W: language processing. Red vs. Green (first two regressors): left hand (LH). Green vs. Red: right hand (RH). The last contrast corresponds to the visual stimulus: Gray = OFF, Red = ON. Numbers indicate the hand used for the corresponding response; (b) IFM paradigm. Exemplary excerpt of the first 45 time points (TP) of the actual regressor used.

Response accuracy was logged to assess compliance and adjust the motor re-

gressors if necessary. Visual activation was modeled using the timing of visual stimuli, whose blocks were partially timewise orthogonalized to the auditory stimuli; motor activation contrasted right-hand versus left-hand responses, which were completely orthogonalized; while language activation contrasted with word versus tone epochs, also orthogonalized (see discussion section for details).

The language regressor included ten 30-second epochs. Across these, 18 synonym pairs and 17 antonym pairs were presented, drawn from a locally developed word bank and recorded in a neutral American male voice. Thus, seven-word pairs (synonyms and antonyms) were presented in each ON epoch. All equal tone pairs were tones of 600 Hz. For the different tone condition, two auditory stimuli were used: a low tone at 600 Hz and a high tone at 1000 Hz, each 400 ms in duration. Tones and word pairs were counterbalanced across the task.

Participants were trained outside the scanner and briefly retested inside before scanning to ensure understanding. Data quality was monitored in real time using the scanner's built-in multiple regressor analysis tool.

## 2.1. Processing

Data was processed using an in-house script built around FSL batch commands. The model included three explanatory variables and four regressors, one of which served as a negative regressor to capture opposite-hand responses. Regressors were constructed under the assumption that each response produces a sustained BOLD signal whose duration exceeds the TR. Consequently, all timepoints within a concordant epoch were coded as "1" in the regressor. This accounts for the mismatch between the number of patient responses and the number of "ON" timepoints—for example, seven responses within an epoch may generate 15 ON timepoints (**Figure 1(b)**). All activation maps were reported using a threshold of  $z = 3.5$ , corresponding to a significance level of  $p = 4.65 \times 10^{-4}$ . No individuals were excluded from the cohort on the basis of low performance, as all patients were evaluated outside the scanner prior to the exam. Only patients able to perform the sample task, consisting of a small subset of the full task, were included ( $N = 118$ ).

## 2.2. Analysis

Each paradigm result was assessed by a single rater (BB) with more than 25 years of experience in clinical fMRI in children. A study was considered successful if canonical functional areas were activated as follows: primary and secondary visual areas for the visual task; posterior middle temporal gyrus, supramarginal gyrus, and/or inferior frontal gyrus (IFG) for the language task; and the contralateral pre- and post-central gyrus at the level of the hand knob for the motor task.

In addition, for each case, lateralization of expressive and receptive language was labeled as L (left) or R (right) based on activation extent and intensity, with ambiguous cases labeled as bilateral (B). Quantitative assessments were not deemed necessary in a clinical setting, given that lateralization indices (LI) vary

significantly depending on two factors: 1) whether measurements are based on hemispheric, lobar or domain-specific areas, and 2) the threshold level [1] [2].

### 3. Results

Children performed the IFM task easily, achieving a response accuracy greater than 80% in the language task. Errors of up to 20% did not substantially affect activation patterns, though they slightly reduced the extent of motor activation. Receptive language activation was successfully obtained in 115 patients (97.5%), while expressive language activation was observed in 101 patients (85.6%). Only one case demonstrated isolated expressive language activation.

Motor and visual paradigms were successful in 113 and 111 cases, corresponding to 95.7% and 94.1%, success rate, respectively (see **Table 1**).

**Table 1.** Observed clinical success rates.

Functional Domain	Success Rate %	Canonical Areas Mapped
Receptive Language	97.5	Middle temporal gyrus (MTG), supramarginal gyrus (SG)
Expressive Language	85.6	Inferior frontal gyrus (IFG)
Motor Function	95.7	Contralateral pre- and post-central gyrus (hand knob)
Visual Function	94.1	Primary and secondary visual areas

Overall, activations obtained with the IFM paradigm appeared cleaner, with less noise and motion artifacts, compared to standard single-task studies (**Figure 2**).

### 4. Discussion

We describe a method (IFM paradigm) that enables the simultaneous assessment of several clinically relevant fMRI tasks within a single 5-minute sequence, achieving sensitivities of more than 94.1% for visual, 95.7% for motor, and 85.6% and 97.5% for expressive and receptive language functions, respectively. The IFM paradigm is well accepted, efficient, sensitive, and highly accurate, significantly reducing total session time.

Longer fMRI sessions increase motion artifacts that degrade image quality, resulting in noisier activations—a common issue, particularly in pediatric populations. The substantially shorter time required for a complete clinical functional assessment with the IFM paradigm minimizes patient motion, improves data quality, and consequently enhances accuracy.

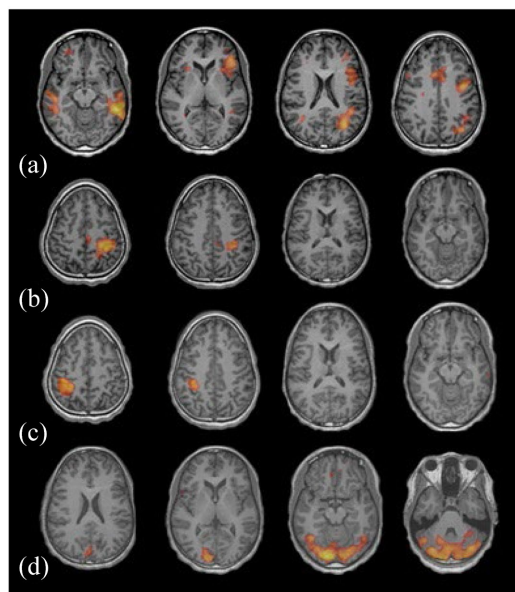
In fMRI, the use of multiple regressors is standard practice [3]-[5]. These regressors typically account for novelty, trends, and global effects. However, the concurrent modeling of multiple independent task conditions within a single acquisition remains underutilized, despite its well-established theoretical foundation [6].

Cortical specialization supports the feasibility of such combined designs. Pri-

primary sensorimotor and visual cortices are unimodal, meaning they respond exclusively to specific types of stimuli, providing functional segregation. In contrast, language networks are multimodal but anatomically segregated and relatively distant from visual and hand-motor areas. This functional organization supports an additional form of “anatomical orthogonalization”, allowing the design of modality-specific regressors within the IFM approach.

Although intermodal co-activations (for example motor activation in tool naming or neonatal auditory-motor coupling) have been documented [7]-[9], their contribution is not significant or not present in older children.

The superior activation of receptive over expressive language areas was expected. It is well established that semantic decision tasks preferentially engage temporal and parietal regions. However, the lexical and phonological components involved in the task may account for the additional activation of regions commonly associated with expressive language functions. This activation, however, comes as a plus, as expressive localization may be dissociated from receptive, and be of crucial importance in frontal resections.



**Figure 2.** Typical activations obtained with the IFM paradigm. Insets show four representative axial slices illustrating significant activation for each task regressor. Activation maps are overlaid on the T1-weighted anatomical MRI. Images are displayed in radiological convention (the left hemisphere appears on the right). (a) Language task (synonym vs. antonym discrimination): Activation in the posterior temporal cortex corresponding to receptive language areas, showing left-hemisphere dominance; left inferior frontal gyrus (IFG) activation corresponding with expressive language area; and additional activation in ancillary language areas, including the bilateral—left-dominant—pre-SMA and left parietal regions (verbal working memory); (b) Right-hand motor task: Activation in the left precentral and postcentral gyri, as well as in the SMA; (c) Left-hand motor task: Isolated activation in the right precentral and postcentral gyri; (d) Visual task: Bilateral activation in the primary and secondary visual areas of the occipital lobes. Apparent posterior fossa activation reflects smoothing and averaging of signal from the basal occipital lobe in the axial plane.

An interesting observation from our experience is that the IFM paradigm yields a cleaner signal compared to single-domain tasks, a feature observable in the exemplary images of **Figure 2**. A possible explanation is that maintaining continuous engagement throughout the sequence reduces cognitive drift during rest blocks—a frequent confound in traditional language fMRI. Of importance is the close monitoring of the patient's performance, made possible by the fact that the patient responds to each event. This allows the practitioner to ascertain the patient's cooperation, understanding of the task, and overall language performance level.

## 5. Further Implementations

To extend the utility of the IFM paradigm, a variant has been developed for use in sedated patients who cannot actively respond. This modified protocol reduces the acquisition time to 3 minutes and 20 seconds, comprising 100 timepoints. Active motor responses are replaced by passive sensory-motor hand stimulation, while the language task involves passive listening to a narrated story divided in blocks. Visual stimulation is delivered using a custom-built device that integrates fiber optics and 3D-printed translucent goggles, which emit light directly onto the eyelids. This adaptation has achieved promising results, with success rates exceeding 80% for language and sensory-motor mapping and 90% for visual cortical activation.

### Validating Results Utilizing a Comparator Task

For the sake of quality and accuracy control, the language activation results of the IFM were compared with the results obtained from an auditorily-presented description task (ADT) that was also given in the same session to all cases. The ADT is based on sentence comprehension. Sentences are presented auditorily in 30-second blocks; half of which are false statements. Subjects press a button for true statements while withholding response for false ones. The control condition consisted of pseudo-sentences—the same sentences played backward—interspersed with 1000 Hz tones (400 ms) that required a button response. This approach was initially our protocol, at the beginning of the utilization of the IFM. Later we have released only in the IFM when activation is robust, localized in the left hemisphere and in right-handed patients. For this comparison, the same rater (BB) evaluated the concordance of language lateralization. Concordant hits were judged per domain (expressive vs receptive) between tasks. Non-concordant hits were judged if for each domain the labels were distinct (R vs L). Bilateral activations without clear hemispheric dominance in the IFM paradigm, compared to any type of left (L) or right (R) lateralization in the comparator task, were considered concordant activations. This approach aligns with the principle that, in clinical practice, false-positive results are less detrimental to patient outcomes, as they may prompt neurosurgeons to adopt a more conservative approach. In contrast, false-negative findings could encourage unnecessarily aggressive interventions.

Of the 118 patients, eight patients failed to show activation on the ADT (93.2% success). This left 110 comparable cases, of which discordant lateralization occurred in 3 receptive and 1 expressive comparison resulting in a 97.3 and 99% concordance, respectively, between IFM and ADT results. Such discordance may be due to qualitative cognitive differences. Cognitive load differs qualitatively across tasks: some rely more on semantic processing, whereas others place greater demands on phonology, prosody, and even pragmatic aspects of language. In addition, patients may adopt different strategies to cope with the task. We also cannot rule out the effects of recent or within-session, unnoticed epileptic activity, which may alter brain responses in some cases. Such effects of seizures on fMRI responses have been documented previously [10].

It is important to note that there is no gold standard task in FMRI for language mapping. However, ADT is a common task utilized for language mapping as it is well controlled, easy to implement and highly sensitive.

## 6. Limitations

The main limitation of the IFM paradigm is the requirement for a customized analysis pipeline. To our knowledge, commercial software packages do not support multi-regressor modeling for more than two contrasts (on-off and off-on) that would accommodate two tasks. Therefore, a technically skilled analyst is needed to tailor the intertwined multiple regressors appropriately.

The task also requires adequate cognitive performance, as semantic decision paradigms involve phonological decoding, lexical access, and extraction. However, this cognitive demand can be advantageous, as it promotes robust activation of core language networks, including expressive regions.

Another limitation is that the IFM paradigm typically yields only contralateral hand activations. Bilateral activations of hand representation areas, sometimes observed in dedicated single-hand paradigms, are not seen here due to cancellation effects inherent to the design. Specifically, any ipsilateral co-activation is eliminated because it occurs during the ON epoch of the contralateral hand. Nevertheless, truly bilateral representations of motor function are generally confined to proximal muscles, whereas distal limb representations (for example, the hand) are predominantly contralateral. Bilateral activations sometimes observed in standard fMRI tasks may instead reflect functional connectivity rather than genuine motor representation and are typically not clinically meaningful for surgical planning.

Finally, in patients with structural lesions or atypical language dominance, targeted standard tasks remain advisable to confirm the IFM results.

## 7. Conclusion

We report our experience with the IFM fMRI paradigm, which combines four functional assessments—language, visual, and bilateral motor—into a single 5-minute sequence. Our clinical experience with more than 100 pediatric epilepsy

patients indicates that the IFM paradigm is efficient, reliable, and well tolerated by children aged 7 years and older. It may serve as a practical and time-efficient screening tool for functional mapping in pediatric populations, particularly when motion or time constraints limit the feasibility of traditional multi-task acquisitions.

## Conflicts of Interest

The authors declare no conflicts of interest regarding the publication of this paper.

## References

- [1] Bradshaw, A.R., Bishop, D.V.M. and Woodhead, Z.V.J. (2017) Methodological Considerations in Assessment of Language Lateralisation with fMRI: A Systematic Review. *PeerJ*, **5**, e3557. <https://doi.org/10.7717/peerj.3557>
- [2] Suarez, R.O., Whalen, S., Nelson, A.P., Tie, Y., Meadows, M., Radmanesh, A., *et al.* (2009) Threshold-Independent Functional MRI Determination of Language Dominance: A Validation Study against Clinical Gold Standards. *Epilepsy & Behavior*, **16**, 288-297. <https://doi.org/10.1016/j.yebeh.2009.07.034>
- [3] Büchel, C., Wise, R.J.S., Mummery, C.J., Poline, J.B. and Friston, K.J. (1996) Nonlinear Regression in Parametric Activation Studies. *NeuroImage*, **4**, 60-66. <https://doi.org/10.1006/nimg.1996.0029>
- [4] Friston, K.J., Holmes, A.P., Worsley, K.J., Poline, J.P., Frith, C.D. and Frackowiak, R.S.J. (1994) Statistical Parametric Maps in Functional Imaging: A General Linear Approach. *Human Brain Mapping*, **2**, 189-210. <https://doi.org/10.1002/hbm.460020402>
- [5] Gitelman, D.R., Penny, W.D., Ashburner, J. and Friston, K.J. (2003) Modeling Regional and Psychophysiologic Interactions in fMRI: The Importance of Hemodynamic Deconvolution. *NeuroImage*, **19**, 200-207. [https://doi.org/10.1016/s1053-8119\(03\)00058-2](https://doi.org/10.1016/s1053-8119(03)00058-2)
- [6] Smith, S.M., Jenkinson, M., Woolrich, M.W., Beckmann, C.F., Behrens, T.E.J., Johansen-Berg, H., *et al.* (2004) Advances in Functional and Structural MR Image Analysis and Implementation as FSL. *NeuroImage*, **23**, S208-S219. <https://doi.org/10.1016/j.neuroimage.2004.07.051>
- [7] Chao, L.L. and Martin, A. (2000) Representation of Manipulable Man-Made Objects in the Dorsal Stream. *NeuroImage*, **12**, 478-484. <https://doi.org/10.1006/nimg.2000.0635>
- [8] Floccia, C., Bertonicine, J. and Christophe, A. (1997) Development of Selective Responses to Mother's Voice in 4-Month-Old Infants. *Developmental Science*, **10**, 138-146.
- [9] Floccia, C., Christophe, A. and Bertonicini, J. (1997) High-Amplitude Sucking and Newborns: The Quest for Underlying Mechanisms. *Journal of Experimental Child Psychology*, **64**, 175-198. <https://doi.org/10.1006/jecp.1996.2349>
- [10] Jayakar, P., Bernal, B., Santiago Medina, L. and Altman, N. (2002) False Lateralization of Language Cortex on Functional MRI after a Cluster of Focal Seizures. *Neurology*, **58**, 490-492. <https://doi.org/10.1212/wnl.58.3.490>