

Retrospective Demographic Analysis of Neurovascular Syndrome—Secondary to: A) Endemic Subacute (Fruits Borne) Viral Infection, Consequent to Global Aborted Blood, Contraceptives Menstrual Blood Pollution; B) Consumption of Waterliving Toxinous Mammals

Elizabeth Jeya Vardhini Samuel, Darmalingam Subbaian, Surianarayanan Natarajan, Ramalingam, Celestine Raj Manohar

Karpagam Faculty of Medical Sciences and Research, Coimbatore, Tamil Nadu, India

Email: elizabethjsamuel@gmail.com

How to cite this paper: Samuel, E.J.V., Subbaian, D., Natarajan, S., Ramalingam and Manohar, C.R. (2020) Retrospective Demographic Analysis of Neurovascular Syndrome—Secondary to: A) Endemic Subacute (Fruits Borne) Viral Infection, Consequent to Global Aborted Blood, Contraceptives Menstrual Blood Pollution; B) Consumption of Waterliving Toxinous Mammals. *Open Journal of Rheumatology and Autoimmune Diseases*, 10, 24-38.

<https://doi.org/10.4236/ojra.2020.101004>

Received: December 3, 2019

Accepted: February 16, 2020

Published: February 19, 2020

Copyright © 2020 by author(s) and Scientific Research Publishing Inc. This work is licensed under the Creative Commons Attribution International License (CC BY 4.0).

<http://creativecommons.org/licenses/by/4.0/>



Open Access

Abstract

15 patients after the middle of 2018, during the initial onset of the epidemic of identified Nipah viral infection (fruits borne virus) in adjacent state, presented with fever, acute coma, delirium, movement disorders, required referral to district headquarters hospital, for virology confirmation, and management. 135 mostly afebrile patients, who refused referral to government hospital, for virology confirmation, presented with symptoms of mainly subacute pan encephalitis, over the past 14 months; 90% presented with conglomeration of vertigo, staring, personality changes, imbalance in gait, difficulty to walk, bilateral drooling of saliva, tremors, confusion, altered sensorium, nausea, vomiting; 83% presented with dysarthria, 28% presented with symptoms of raised intracranial pressure-mimicking accelerated, malignant hypertensive emergencies, bradycardia, vomiting; decreased vision in 4.6%, myoclonic jerks in 58%, choreoathetosis in 8%. All of them could not afford INR 10000 for virology confirmation. Fruits borne viral subacute pan encephalitis, can present as subacute neurovascular syndrome, simulating ischemic stroke, mediated by Hapten triggered autoimmune angiopathy (blood borne) with resultant bilateral, asymmetrical multifocal, infarcts, cerebritis with consequent edema, requiring recognition, successful treatment with acyclovir, antiedema, antiepileptic measures and not antiplatelets, since the etiology is inflammatory and not degenerative.

Promoting awareness to steam cook, pressure cook, cook with coconut oil (pie) fruits, steaming fresh fruit juices, before consumption will prevent incidence of fruits borne, tobacco leaves borne, and endemic viral infection. Economical screening card tests for Nipah fruits borne virus, will enable early detection, authenticate notification, early recognition treatment of subacute pan encephalitis presenting as neurovascular syndrome, mimicking ischemic stroke Global aborted blood pollution, contraceptive menstrual blood pollution, documented by rising environmental estrogen, beta human chorionic gonadotropins, alpha fetoprotein, favours emergence, virulence, drug resistance of microbes, including the recent fruits borne virus; global eradication of contraception, abortion (—non-evidence-based medical practice, without therapeutic indication, therapeutic protocols, therapeutic policies), to be replaced by global baby boom (promoting childbirth >10 - 20 children per family) will prevent further emergence, virulence of microbial infections, including Nipah, oncoming Ebola corona. Over the past 5 years, consumption of water living without scales, gills, fins,-toxin containing mammals, presented as cortical venous, sigmoid sinus thrombosis, in 3.5%, choreoathetosis in 12.5%, unresponsive but restless in 12.5%, quadriparesis, hemiparesis in 37.5% mimicking neurovascular syndrome, ischemic stroke; treatment with methylprednisolone, immunoglobulin reverted.

Keywords

Subacute Pan Encephalitis, Neurovascular Syndrome, Autoimmune Vasculitis/Angiopathy

1. Introduction

Initially when acute encephalitis, by fruits borne viral infection—Nipah, was identified, notified, in middle of 2018, in the neighbouring state, around 15 patients over a span of 2 - 3 months, had come with manifestations of fever, coma, choreoathetosis, myoclonic jerks, epilepsy partialis continua, evidenced by cerebral imaging with multifocal, bilateral, asymmetrical infarcts, extensive cerebral edema, they were referred to district headquarters hospital for virology confirmation and management.

2 - 3 months after the onset of Nipah virus epidemic, many afebrile patients presented with dysarthria, staring, personality changes, less communicative, drooling of saliva, vertigo, giddiness, vomiting, altered sensorium, staggering gait, hemiparesis, monoparesis, of few days to few weeks duration, association with fresh fruits, fresh fruit juices consumption history, refused referral to district headquarters hospital, and did not have resources to get virology confirmation ~INR 10000; cerebral imaging evidenced subacute bilateral, asymmetrical infarcts, bilateral, extensive cerebral edema; on treatment with antiviral, coupled with antiedema, antiepileptics, remarkable, gratifying cure for the endemic fruits borne viral infection was achieved.

2. Objective

Later on when one of two patients who were treated for nearly 1.5 months for ischemic stroke with antiedema, elsewhere, and were referred to our hospital, due to persisting altered sensorium, for further management; could not be convinced to consume antiviral treatment, to treat the fruits borne virus presenting as subacute stroke with, staring, altered sensorium, imbalance in gait, he succumbed (continued to consume raw fresh fruits, juices), to tonsillar herniation, by the progressive cerebral edema of subacute encephalitis, which went unchecked, the other patient who could be convinced to take antiviral treatment recovered remarkably, within 48 - 72 hours.

Hence this retrospective demographic analysis is undertaken with the objective to highlight the subacute encephalitis manifestations of endemic fruits borne viral infection, presenting as neurovascular syndrome, as differential diagnosis to ischemic stroke, to enable recognition, treatment, cure and implement preventive measures.

For the past 4 - 5 years, secondary to consuming water-living without scales, gills, fins-toxin containing water living mammals, misconceived as fish, a few patients presented with choreoathetosis, altered sensorium, quadriparesis, simulating ischemic stroke, by molecular mimicry mediated autoimmune vasculitis, (micro or macroangiopathy) received treatment with methyl prednisolone and reverted.

Hence this retrospective analysis includes consumption of water living without scales, presenting as neurovascular syndrome, as differential diagnosis to ischemic stroke.

3. Materials, Methods, Analysis and Results

15 patients presented with acute coma, during the initial phase of notified, identified fruits borne virus-Nipah in adjacent state (**Figure 1**).

For the past 14 months, after fruits borne virus has emerged, become endemic, secondary to aborted blood pollution, contraceptive (non evidence based medical practice) menstrual blood pollution, evidenced by rising environmental (air, waters of rivers, oceans) estrogen, alpha feto protein, beta human chorionic gonadotropin, representing maternal blood, fetal blood, placental blood (trophoblastic elements), and not industrial emissions, or industrial waste, 135 patients, presented with symptoms of subacute encephalitis, simulating suspicious ischemic stroke; of them 90% presented with conglomeration of vertigo, staring, difficulty to walk, personality changes, imbalance in gait, drooling of saliva, tremors, confusion, altered sensorium, vomiting; 83% presented with dysarthria, 28% presented with, symptoms of raised intracranial pressure-mimicking accelerated (**Figure 1**), malignant hypertensive emergencies, bradycardia, vomiting; decreased vision in 4.6%, myoclonic jerks in 58%. choreoathetosis in 8%.

Over the past 5 years, consumption of water living without scales, gills, fins-toxin containing mammals, presented as (**Figure 2**) cortical venous, sigmoid sinus

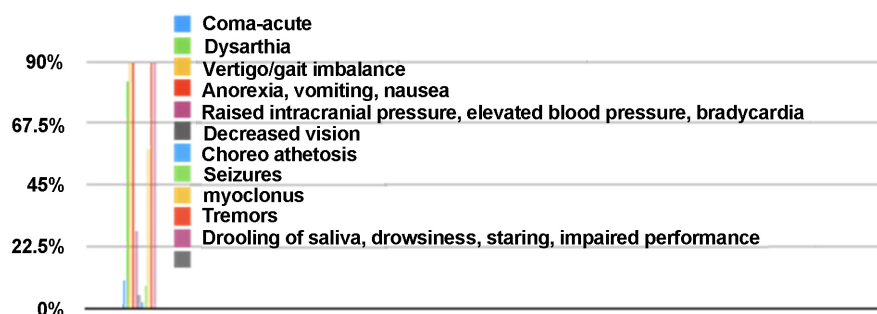


Figure 1. Analysis of neurovascular syndrome—autoimmune angiopathy (haptan mediated) fruits borne viral subacute pan encephalitis.

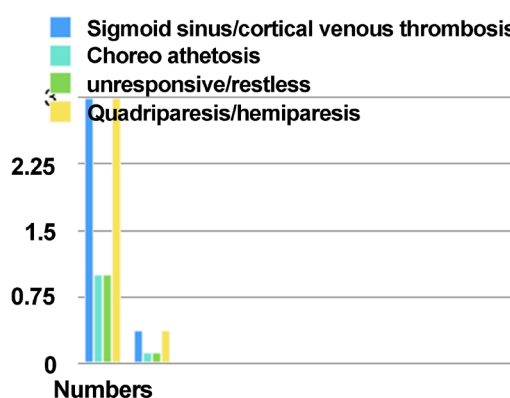


Figure 2. Analysis of neurovascular syndrome—autoimmune Angiopathy (molecular mimicry mediated) secondary to consumption of toxinous water living mammals.

thrombosis in 3.5%, choreoathetosis in 12.5%, unresponsive but restless in 12.5%, quadriparesis, hemiparesis in 37.5% mimicking neurovascular syndrome.

The other non neurological complications seen (**Figure 3**) after consumption of toxin containing water living without scales, gills, fins, mediated by autoimmune angiopathy, namely pancytopenia seen in 20%, haemolytic jaundice in 20%, nephritis in 30%, hepatocellular cancer in 5%, abdominal lymphoma, chronic lymphatic leukaemia in 6%, cholangiocarcinoma in 7%, acute kidney injury requiring urgent hemodialysis in 7%, kikuchi disease or cervical lymphadenopathy was seen in 8%, infiltrative hepatopathy in 4%; since molecular mimicry mediated vasculitis secondary to toxins contained, in the water living mammals, resulted in these above diseases, treatment with methyl prednisolone, coupled with supportive therapy offered gratifying results.

90% of the people presenting with pancytopenia, haemolytic jaundice, were not on contraception; pancytopenia, haemolytic jaundice completely reverted, with parenteral pulse therapy of Methyl Prednisolone 1 gm intravenous, given once daily for 3 days, followed by supportive packed red blood cell transfusion. 10% of them with pancytopenia, contraception (germ cells fragmentation to chromatid breaks, ring chromosomes, secondary to contraception leads to 275% increase in autoimmunity), hence they required immunoglobulin, methyl prednisolone alone couldn't revert to normalcy as in non-contracepted people.

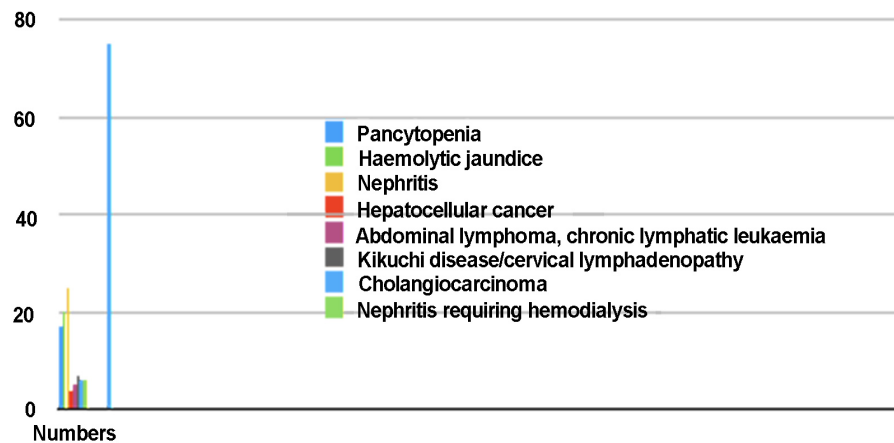


Figure 3. Some of the non neurological complications—autoimmune angiopathy (molecular mimicry mediated) by consumption of water living toxins containing mammals.

Repeated ingestion of toxins of water living without scales, gills, fins, other toxins to include-horsegrams, mushrooms, custard, seaweeds, sprouted seeds, raw carrot, beetroot (molecular mimicry mediated autoimmunity) results in infiltrative hepatopathy, with significantly elevated alkaline phosphatase, suspected, to be followed up for hepatocellular carcinoma, abdominal lymphadenopathy, to be followed-up for abdominal lymphoma; of them people without contraception 100% reverted with methyl prednisolone, with alkaline phosphatase reaching normal levels.

4. Discussion

Fever with altered sensorium, denotes meningitis, can have headache [1], photophobia, meningism; if one or more of the three are associated, namely neurological deficit, or seizures, or movement disorder, then meningo-encephalitis needs to be considered.

Clinical features of nervous system infections, depend upon the location of the infections [1] (the meninges or the parenchyma of the brain and the spinal cord) the causative organism (virus, bacterium, parasite) and whether the infection is acute or chronic.

Infection of the substance of the nervous system will produce symptoms of [1] focal dysfunction (focal neurological deficits and/or seizures) with general signs of infection, depending upon the acuteness of the infection and the type of organism. Disturbances of consciousness [1] ranging from drowsiness to deep coma, supervenes early and may advance dramatically.

Systemic (blood borne) viral infection results in multifocal, asymmetrical, bilateral infarcts mediated by Hapten triggered autoimmune [2] vasculitis and direct brain parenchymal infection (cerebritis) leading to bilateral, extensive [3] cerebral edema, correlating with the severity of infection.

Cerebrospinal fluid examination is contraindicated in the presence of cerebral edema, cerebral infarcts, hemorrhage, structural pathology in the brain, mass ef-

fect, ventriculomegaly, mass lesion, detected by neuroimaging, fundoscopy and clinical examination. Virological investigations, of the cerebrospinal fluid, serum, including PCR for viral DNA, may reveal the causative organism.

Initiation of treatment [1] should not await, demonstration of the causative organism.

Viral encephalitis is a parenchymal infection of the brain, almost invariably associated with meningeal [2] inflammation and sometimes with simultaneous involvement of the spinal cord. Some viruses tend to infect the nervous system, such neural tropism takes several forms, some viruses infect specific cell types (oligodendrocytes) while others involve particular areas of the brain (medial temporal lobes and limbic systems).

Systemic viral infections, in the absence of direct evidence of viral penetration to central nervous system, follow immune mediated disease such as perivenous demyelination (acute disseminated encephalomyelitis and acute necrotising hemorrhagic encephalomyelitis). Hence anti platelets are contraindicated in subacute forms of encephalitis presenting as infarcts, perivenous demyelination, since hemorrhagic presentation, transformation is common in inflammatory etiology.

Encephalitis refers to diffuse inflammation of the brain with a parenchymal infiltration of inflammatory cells, usually caused by a virus; the brain damage caused by acute infective encephalitis is due to a combination of intracellular viral growth and the hosts [3] inflammatory response; early in the disease CT and MRI findings may be normal; MRI may reveal hyper intensity in the white matter on T2 weighted images; the findings are often bilateral, asymmetrical, as multifocal infarcts, foci of cerebral edema.

Cells or tissues may undergo [4] antigenic alterations, as a result of physical, chemical and biological influences; such altered neoantigens may elicit an immune response; neoantigens can arise by physical agents as irradiation, photosensitivity, cold allergy, viral infections and bacterial enzymes.

Haptens are antigenic substances, that react with an antibody; there are wide variety of features that determine immunogenicity, recognition of foreignness; generally molecules recognised as self are not immunogenic; to be immunogenic, molecules must be recognised as foreign; most potent immunogens are usually large complex proteins; molecules with molecular weight less than 10,000 are not immunogenic; small molecules called Haptens [5] become immunogenic only when linked in a carrier protein; e.g. lipids, aminoacids are non immunogenic; they require conjunction with carrier protein or polysaccharide before immunogenic or generate an immune response.

1990s a new genus Henipa virus was detected in an outbreak in Australia, Malaysia; two zoonotic paramyxoviruses, were found to be associated with zoonotic outbreaks. Fruit bats are their natural hosts, one [6] of them is Nipah virus; in Malaysia severe encephalitis was caused by this virus, with direct transmission from pigs to humans; mortality was high; death of many horses occurred in Australia; some human cases were also reported.

Cerebrovascular disease (neurovascular syndrome), denotes any abnormality of the brain caused by a pathologic process [7] of blood vessels; cerebrovascular disease from clinical point of view, includes 3 major categories-thrombosis, embolism, haemorrhage; stroke is a clinical designation that applies to all these conditions particularly, when symptoms begin acutely. Hypoxia, ischemia, and infarction resulting from impairment of blood supply and oxygenation of Central nervous tissue; haemorrhage results from rupture of central nervous tissue blood vessels.

In global ischemia, brain is swollen, gyri are widened and sulci are narrowed; cut surface shows poor demarcation between grey and white matter; histopathology shows, irreversible ischemic injury; early changes seen in 12 - 24 hours-acute neuronal cell change (red neurons), characterised by micro vacuolisation, later nuclear pyknosis and karyorrhexis. Similarly acute changes in oligodendroglia and astrocytes occur somewhat later. Pyramidal cells of the hippocampus, purkinje cells in the cerebellum, pyramidal neurons of neocortex are the most susceptible to global ischemia of short duration.

After acute injury, reaction to tissue damage, begins by infiltration by neutrophils; subacute injury occurring at 24 hours to 2 weeks, include necrosis of tissue, influx of macrophages, vascular proliferation, reactive gliosis; repair seen after approximately 2 weeks is characterised by removal of all necrotic tissue, loss of normally organised central nervous structure and gliosis.

Infarction (neurovascular syndrome) occurs by obstruction of [8] local blood supply; cerebral arterial occlusion leads to focal ischemia, if sustained then leads to infarction of specific region of central nervous tissue within the territory of distribution of the compromised vessel, the size, location, shape of the infarct, extent of tissue damage that results from focal cerebral ischemia by occlusion of blood vessel are determined by modifying factors, specially the adequacy of collateral flow. Thrombosis mainly due to atherosclerosis, common sites is carotid bifurcation, origin of middle cerebral artery, either end of basilar artery, evolution of arterial stenosis.

Variety of inflammatory process that involves blood vessels (neurovascular syndrome) lead to luminal compromise and cerebral infarcts; arteritis of small and large vessels was most commonly seen in association with tuberculosis, syphilis, infectious vasculitis, commonly seen in immunosuppressed and opportunistic infections. Polyarteritis nodosa and other collagen vascular diseases involve cerebral vessels and cause single or multiple infarcts, throughout brain.

Embolism to brain occurs from variety of origins, common sources-myocardial infarct, valvular disease, atrial fibrillation, resulting in multifocal infarcts, by showers of emboli.

Cerebral Amyloid angiopathy, in which amyloidogenic peptides, nearly always the same one found in Alzheimer's disease, deposit in walls of medium and small calibre meningeal, cortical vessels. This deposition can result in weakening of the vessel wall and risk of haemorrhage.

A number of mechanisms have been postulated, such as cross reactivity between

the infectious [9] pathogen or immunogen (e.g. consumed horse grams—legumes, water living without scales gills fins containing toxins, mushrooms, sea weeds (food meant for sea living mammals, whales) custard, sprouted uncooked seeds, uncooked carrot, beet root requiring renin for digestion being absent in humans, present in cattle) and self determinants-molecular mimicry, and release of toxins, sequestered antigens, which are not visible to the immune system; this molecular mimicry mediated [10] autoimmune vasculitis results in multifocal infarcts.

Neurovascular syndrome comprises of pathology in cerebral parenchyma secondary to vascular etiology; infarcts can be secondary to thrombosis, (degenerative) embolism (multifocal), haemorrhage, or tuberculous endarteritis (inflammatory), Haptens (viral, bacterial enzymes) triggered autoimmune vasculitis as in viral acute, subacute encephalitis, molecular mimicry mediated autoimmune vasculitis (secondary to consumption of toxin containing water living without scales, gills, fins-mammals, horse grams-legumes, sprouted uncooked pulses, raw carrot, beetroot (meant for cattle) custard, seaweeds, mushrooms) with consequent multifocal infarcts; collagen vascular diseases resulting in autoimmune vasculitis (highly prevalent after contraception, abortion-non evidence based medical practice-resulting in destruction of germ cells to fragmented [11] chromatids, acentric fragments, ring chromosomes, identified as foreign, with consequent soaring autoimmunity, SIRS-Systemic inflammatory response syndrome).

Hence any of the above neurovascular syndrome presentations can mimic an ischemic stroke; effective therapeutic approach is possible only when neurovascular syndrome or apparent ischemic stroke or infarction's etiology is analysed, comprehended, authenticated, and addressed.

Infarcts secondary to thrombosis present with abrupt onset, arising from degenerated vessel wall, and requires anti platelets in low dose for treatment.

Whereas blood borne acute, subacute viral encephalitis, mediated by Haptens triggered autoimmune vasculitis, resulting in multifocal asymmetrical bilateral infarcts, mimicking ischemic stroke-neurovascular syndrome, requires antiviral, anti edema, anti epileptic treatment; anti platelets, steroids are contraindicated, considering the inflammatory etiopathogenesis.

22 years young lady presented with left sided chest pain, high grade fever with dry cough of one month duration, with left sided epilepsy partialis continua of 4 days duration; old status left hemiparesis of 9 years duration, (occurred at 13 years of age, MRI brain had shown, right middle cerebral artery territory extensive infarct) was present; chest x-ray showed left sided massive pleural effusion; the etiology being tuberculous endarteritis-inflammatory pathology, resulted in middle cerebral artery territory infarct, but inadvertently treated with antiplatelets (indicated in degenerative etiology-thrombotic infarct, degenerative etiology can come only after 37 years of age when our oestrogen-cell metabolism governing hormone reduces from 100 pgm to 15 pgm, leading to degenerative changes in every tissue), hence she had menorrhagia with hemoglobin of 3 gm%; what needs to be highlighted here is tuberculous endarteritis-inflammatory pathology pre-

senting as infarct mimicking ischemic stroke, -neurovascular syndrome—needed to be treated with antituberculous medications, and not anti platelets, recognising the etiopathogenesis, which had resulted in menorrhagia, severe anaemia; this person received antituberculous therapy, pleural effusion, disappeared totally by six weeks (as mentioned, any tuberculosis, with empirical treatment of six weeks duration will become asymptomatic), but 1.5 years treatment in pulmonary tuberculosis and 2 years treatment in extra pulmonary tuberculosis in non contracepted people with unimpaired genomic repertoire will achieve 98% cure of tuberculosis 30 years old lady, had delivered 34 days prior, precious pregnancy after 11 years of infertility; she was fed with love and concern baby shark food (water living without scales, gills, fins—toxin containing mammal) to increase breast milk production; (prevalent social ignorance) within half hour, she was brought with quadriparesis—mimicking ischemic stroke and unresponsiveness. Magnetic resonance imaging, Magnetic resonance arteriogram, revealed multifocal macroarteritis (blood borne toxins mediated inflammatory etiology) with multifocal infarcts, (neurovascular syndrome) multifocal, bilateral narrowing of arteries; she required treatment with methyl prednisolone, intravenous immunoglobulin at 0.4 gm/kg/day, ventilator support, and was referred at patients request. Here the etiology of neurovascular syndrome is molecular mimicry mediated autoimmune vasculitis, secondary to consumption of toxin containing mammals, misconceived as fish.

Eight out of nine patients [12] treated empirically with parenteral acyclovir survived, during an outbreak of Nipah virus infection, among abattoir workers in Singapore in 2009.

It has become common medical practice to initiate acyclovir [13] treatment in every patient with suspected infective encephalitis. Neuropsychiatry symptoms predominate in encephalitis, e.g. hallucinations, psychosis, personality changes, agitation, restlessness, confusion.

Subacute fruit borne viral infections, depending upon the inoculum of virus in the fruits, injected by fruits bat biting, frequency of bats' bites, the quantum of fruits ingested, and the frequency of fresh fruits or fresh fruit juices consumption, are observed for the past 14 months after Nipah fruits borne virus was detected (due to rising unchecked aborted blood pollution, contraceptive menstrual blood pollution) and has become endemic; hence subacute, milder, manifestations of viral encephalitis are seen in individuals with fresh fruits or fresh fruit juices consumption history. Hence patients with toddy, ethanol consumption with bats biting more frequently, presented with severe disease like coma, cerebral hemispheric edema, infarcts. Tremors of ethanol dependent status in addition to thiamine, methylcobalamin supplementation, required acyclovir—antiviral treatment to bring about cure, after fruits borne virus' endemicity.

Bats bitten tobacco when inhaled, results in carditis, acute respiratory distress syndrome.

Fruits borne virus entering through the gut, produces gut related symptoms, then blood borne, infects the central nervous tissue by the following mechan-

isms, namely Hapten (virus linked in to cells' polysaccharides or protein to become immunogenic) triggered autoimmune vasculitis producing, multifocal bilateral, asymmetrical infarcts; direct invasion, infection of brain parenchyma, to produce extensive bilateral cerebritis, edema, periventricular ooze, (subacute pan encephalitis) can progress slowly with repeated fresh fruits, fresh fruit juices consumption, life threatening transtentorial, or tonsillar herniation.

In the initial phase of epidemic (beyond the middle of 2018) of fruits borne virus—Nipah 15 patients presented with acute symptoms, of choreoathetosis, coma, fever, myoclonic epilepsy, requiring referral to district government headquarters hospital for virology confirmation and management, seven of these patients were ethanol, toddy consumers wherein fruits bats repeated biting, with higher viral load had presented in acute coma.

135 mostly afebrile patients, who refused referral to district Government head quarters hospital, with associated history of consumption of fresh fruits, fresh fruit juices, presented (after October, November 2018—a few months later) with subacute encephalitis manifestations of few days to few weeks duration; of them 90% presented with conglomeration of vertigo, staring, personality changes, imbalance in gait, difficulty to walk, drooling of saliva, tremors, confusion, altered sensorium, nausea, vomiting; 83% presented with dysarthria; 28% presented with symptoms of raised intracranial pressure-mimicking accelerated, malignant hypertensive emergencies, bradycardia, vomiting; decreased vision in 4.6%, myoclonic jerks in 58%, choreoathetosis in 8%. All of them could not afford INR10000/fo virology confirmation.

CT scan brain (**Figure 4**), showed bilateral asymmetrical subacute, acute infarcts, involving, prefrontal, bioccipital, bicerebellar regions, entire brain (subacute pan encephalitis); extensive cerebral edema, periventricular ooze, effaced echo texture by the cerebral edema, with compression of third fourth ventricle, resultant bilateral ventriculomegaly, elevated intracranial pressure, ultimately resulting in transtentorial, or tonsillar herniation; there were associated pancytopenia, leukopenia, elevated liver enzymes because the toxins of blood borne virus damages the blood cells, also gut entered fruits borne virus pass through portal circulation in the liver, before entering systemic circulation, producing hepatocellular damage.

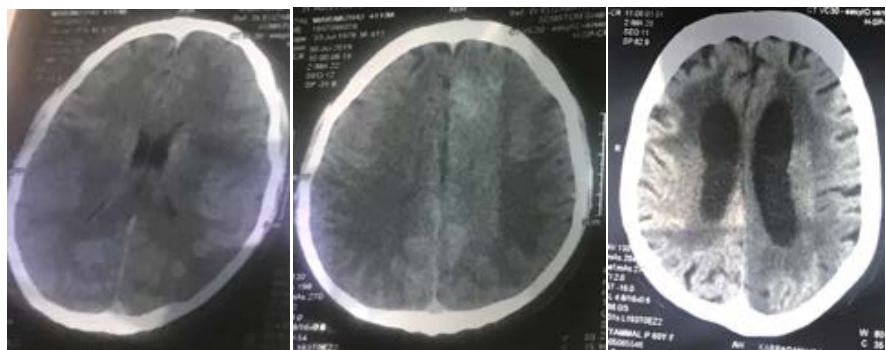


Figure 4. CT scan brain.

These 135 patients, presenting with subacute pan encephalitis refused referral to government district headquarters hospital, for virology confirmation. None could afford (INR-10,000) towards the estimation of NIV—serum IgG, IgM, or PCR.

They were treated with oral acyclovir 800 mg q5h for 14 days, combined with antiedema measures, anti epileptic therapy and remarkably recovered, except for one patient presenting at 1.5 months into the illness, having been treated for ischemic stroke elsewhere, but sensorium or difficulty to walk, had not improved, his relatives wanted only the ischemic stroke treatment, fresh fruit juices consumption continued, he succumbed on the 14th day after admission, with raised intracranial pressure, and herniation; he did not process virology confirmation either.

Environmental aborted blood, contraceptive menstrual blood pollution, documented by rising [14] [15] [16] environmental oestrogen, alpha fetoprotein, beta human chorionic gonadotropin, has favoured, virulence, drug resistance of microbes, emergence of new microbes, namely dengue, H1N1 (swine flu), kysanur forest disease (monkey flu), birds flu, Nipah virus (fruits bat flu) from after 2000—announcing “Health for all” and having implemented permanent sterilisation to every human including those on the foothills and tribes; contraception, abortion are non-evidence-based medical practice, *i.e.*, no therapeutic indication, no therapeutic protocols, or no therapeutic policies, hence cannot be part of noble medical curriculum, which is framed, devised and exists to save lives from the jaws of death and diseases only.

Global contraception reversal, halt of abortions, to be replaced by global baby boom as >10 - 20 children per family, will remove [14] further increase in blood pollution and can curtail emergence, virulence, drug resistance of microbes including Nipah, and oncoming Ebola corona.

Recognition of endemic fruits borne virus—Nipah, presenting as subacute milder forms depending on the frequency of fruits, fruit juices consumed, and the inoculum of virus ingested is essential, and antiviral, antiedema treatment brings gratifying cure.

Fresh fruits, fresh fruit juices consumption to be replaced by cooking, steaming pressure cooking in idli pan or frying in virgin coconut oil—to make a pie, the fruits, steaming fresh fruit juices before consumption to eliminate the virus; this awareness needs to be promoted, hereafter with blood pollution, absence of 10 - 20 children per family, having invited endemicity of fruits bat virus Nipah for the past 14 months, the privilege of fresh fruits, fresh fruit juices consumption is lost and needs to be replaced by cooking, steaming, pressure cooking in virgin coconut oil—fruits, fruit juices before consumption, to prevent subacute pan encephalitis.

Promoting 10 - 20 childbirth per family, global baby boom resolution, will prevent emergence, drug resistance, virulence, of microbes, including Nipah, Ebola corona; the carbon dioxide exhaled by birth of millions, trillions of human [14] lives replenishes ozone, brings monsoon rains, provides human resources

for flourishing economy, robust health in cells [17] of parents (autoimmune, degenerative, neoplastic infectious diseases of contraception, abortion will be nullified); tubal recanalisation to be offered with festive spirits to restore health back in cells of contracepted people, reduce blood pollution, replacing with human lives, by baby boom.

Economical screening tests, easily available tests, to be developed for Nipah fruits borne virus-fruits bat's flu virus, so as to enable detection, notification, authenticate confirmation, to enable early recognition and treatment by medical fraternity.

Over the past 5 years, consumption of water living without scales, gills, fins-toxin containing mammals, presented as cortical venous thrombosis, sigmoid sinus thrombosis in 3.5%, choreoathetosis in 12.5%, unresponsive but restless in 12.5%, quadriparesis, hemiparesis in 37.5% mimicking neurovascular syndrome.

The other non neurological complications seen after consumption of toxin containing water living without scales, gills, fins, molecular mimicry mediated autoimmune angiopathy, namely pancytopenia was seen in 20%, haemolytic jaundice in 20%, nephritis in 30%, hepatocellular cancer in 5%, abdominal lymphoma, chronic lymphatic leukaemia in 6%, cholangiocarcinoma in 7%, acute kidney injury requiring urgent hemodialysis in 7%; kikuchi disease or cervical lymphadenopathy was seen in 8%, infiltrative hepatopathy in 4%; since molecular mimicry mediated vasculitis secondary to toxins contained, in the water living mammals, resulted in these above diseases, added treatment with methyl prednisolone offered gratifying results.

90% of the people presenting with pancytopenia, haemolytic jaundice, were not on contraception; pancytopenia, haemolytic jaundice completely reverted, with parenteral pulse therapy of Methyl Prednisolone 1 gm intravenous, given once daily for 3 days, followed by supportive packed red blood cell transfusion. 10% of them with pancytopenia, [18] contraception (germ cells fragmentation to chromatid breaks, ring chromosomes, secondary to contraception leads to 275% increase in [18] autoimmunity), required immunoglobulin, since methyl prednisolone alone couldn't revert to normalcy as in non contracepted people.

Repeated ingestion of toxins of water living without scales, gills, fins (other toxins to include-horsegrams, mushrooms, custard, seaweeds, sprouted seeds, raw carrot, beetroot-molecular mimicry mediated autoimmunity) results in infiltrative hepatopathy, with significantly elevated alkaline phosphatase, suspected, to be followed up for hepatocellular carcinoma, abdominal lymphadenopathy, to be followed-up for abdominal lymphoma; of them people without contraception 100% reverted with methyl prednisolone, with alkaline phosphatase reaching normal levels.

5. Conclusions

Latter half of August 2018, 15 patients presented with fever, unconsciousness, choreoathetosis, myoclonic epilepsy; encephalitis, was considered; they were referred to district government headquarters hospital for virology confir-

mation and management for acute encephalitis; seven of these patients were ethanol, toddy consumers wherein fruits bats repeated exposure, with higher viral load had presented in acute coma.

This happened after a few weeks of, detection, identification of fruits bats' borne virus, fresh fruits borne, fresh fruits juices borne virus Nipah—in adjacent state, August 2018. Computerised axial tomography scans had confirmed possibility of encephalitis.

For the past 14 months, 135 mostly afebrile patients, who refused referral to government hospital for virology confirmation, presented with symptoms of subacute pan encephalitis, simulating ischemic stroke, as neurovascular syndrome.

Demographic analysis of symptoms showed, 90% presented with conglomeration of vertigo, staring, personality changes, imbalance in gait, difficulty to walk, bilateral drooling of saliva, tremors, confusion, altered sensorium, nausea, vomiting; 83% presented with dysarthria, 28% presented with symptoms of raised intracranial pressure, mimicking accelerated, malignant hypertensive emergencies, bradycardia, vomiting; decreased vision in 4.6%, myoclonic jerks in 58%, choreoathetosis in 8%. All of them did not afford INR 10000 for virology confirmation.

Computerised axial tomography scans of brain showed bilateral asymmetrical multifocal (bioccipital, bicerebellar, biprefrontal, bitemporal subacute infarcts, edema) bilateral extensive cerebral edema seen as extensive periventricular ooze, effaced gyri sulci echotexture, compressing the third ventricle with bilateral ventriculomegaly.

Fruits borne virus has become endemic for the past 14 months. Hapten-viral mediated autoimmune vasculitis/angiopathy resulting in multifocal bilateral asymmetrical cerebral, cerebellar parenchymal infarcts, and blood borne (systemic) cerebral infection presenting as bilateral cerebral edema, cerebritis, presenting as neurovascular syndrome, subacute panencephalitis, mimicking ischemic stroke.

Antiviral tablet acyclovir 800 mg Q5H was given for 14 days, with antiedema, anti epileptic medications; gratifying cure was accomplished. This demographic analysis of mild varied symptoms of subacute pan encephalitis, neurovascular syndrome, mimicking ischemic stroke, needs to be identified as secondary to fruits borne virus, and treated early effectively to achieve dramatic cure.

Hereafter with aborted blood, contraceptive menstrual blood pollution (documented by rising environmental estrogen, alpha feto protein, beta human chorionic gonadotropin), absence of 10 - 20 children per family, small family norms, having invited endemicity of fruits bat virus Nipah for the past 14 months, the privilege of fresh fruits, fresh fruit juices consumption is lost for Indian soil, and needs to be replaced by cooking, steaming, pressure cooking, frying fruits, fruit juices before consumption, to prevent subacute pan encephalitis.

Promoting 10 - 20 childbirth per family, global baby boom resolution, will prevent emergence, drug resistance, virulence, of microbes, including Nipah, Ebola corona; the carbon dioxide exhaled by birth of millions, trillions of human lives replenishes ozone, brings monsoon rains, provides human resources for

flourishing economy, robust health in cells of parents (autoimmune, degenerative, neoplastic infectious diseases of contraception, abortion will be nullified) tubal recanalisation to be offered with festive spirits to restore health back in cells of contracepted people, reduce blood pollution, replacing with human lives, by baby boom.

Economical screening tests, easily available tests, to be developed for Nipah fruits borne virus-fruits bat's flu virus, so as to enable detection, notification, authenticate confirmation, to enable early recognition and treatment by medical fraternity.

Similarly neurovascular syndrome mimicking ischemic stroke was detected after consumption of toxin containing water living mammals, for the past 5 years, mediated by molecular mimicry mediated angiopathy; presented as cortical venous thrombosis, sigmoid sinus thrombosis in 3.5%, choreoathetosis in 12.5%, unresponsive but restless in 12.5%, quadriparesis, hemiparesis in 37.5%.

The other non neurological complications seen after consumption of toxin containing water living without scales, gills, fins, mediated by autoimmune angiopathy, namely pancytopenia was seen in 20%, haemolytic jaundice in 20%, nephritis in 30%, hepatocellular cancer in 5%, abdominal lymphoma, chronic lymphatic leukaemia in 6%, cholangiocarcinoma in 7%, acute kidney injury requiring urgent hemodialysis in 7%; kikuchi disease or cervical lymphadenopathy was seen in 8%, infiltrative hepatopathy in 4%; since molecular mimicry mediated vasculitis secondary to toxins contained, in the water living mammals, resulted in these above diseases, added treatment with methyl prednisolone offered gratifying results.

90% of the people presenting with pancytopenia, haemolytic jaundice, were not on contraception; pancytopenia, haemolytic jaundice completely reverted, with parenteral pulse therapy of Methyl Prednisolone 1 gm intravenous, given once daily for 3 days, followed by supportive packed red blood cell transfusion. 10% of them with pancytopenia, contraception (germ cells fragmentation to chromatid breaks, ring chromosomes, secondary to contraception leads to 275% increase in autoimmunity), hence they required immunoglobulin, methyl prednisolone alone couldn't revert to normalcy as in non contracepted people, with unimpaired genomic repertoire.

Conflicts of Interest

The authors declare no conflicts of interest regarding the publication of this paper.

References

- [1] Allen, C.M.C., Leuck, C.J. and Dennis, M. (2010) Infections of the Nervous System, Neurological Disease. In: *Davidson's Principles and Practice of Medicine*, 21st Edition, Churchill Livingstone, Elsevier, Edinburg, London, 1205-1209.
- [2] Frosch, M.P., Anthony, D.C. and Girolami, U.D. (2010) The Central Nervous System. In: *Pathologic Basis of Disease*, 8th Edition, Saunders, Philadelphia, Chapter 28, 1302.

- [3] Zee, C.S., Lgo, J., Kim, P., Segall, H.D. and Ahmadi, J. (2003) Cerebral Infections, Inflammation. In: *CT and MR Imaging of the Whole Body*, Volume 1, 4th Edition, Mosby Publishers, St. Louis, Chapter 6, 210-213.
- [4] Ananthanarayan and Paniker (2013) Textbook of Microbiology. 9th Edition, Universities Press Publisher, Hyderabad, Chapter 18, 179.
- [5] Melnick, J. and Adelbergs (2016) Medical Microbiology. Immunology. 27th Edition, McGraw Hill, New York, Chapter 2, 132.
- [6] Ananthanarayan and Paniker (2013) Textbook of Microbiology. 9th Edition, Universities Press Publisher, Hyderabad, 55th Chapter, 514.
- [7] Frosch, M.P., Anthony, D.C. and De GiroLami, U. (2006) The Central Nervous System. In: *Pathologic Basis of Disease, Robbin's and Cotran*, 7th Edition, Saunders, Elsevier, Philadelphia, Chapter 28, 1361.
- [8] Frosch, M.P., Anthony, D.C. and Girolami, U.D. (2006) The Central Nervous System. In: *Pathologic Basis of Disease, Robbin's and Cotran*, 7th Edition, Elsevier Saunders, Philadelphia, Chapter 28, 1363.
- [9] Marshall, S.E. (2010) Immunological Factors in Disease. In: Colledge, N.R., Walker, B.R. and Ralston, S.H., Eds., *Davidson's Principles and Practice of Medicine*, 21st Edition, Churchill Livingstone, Elsevier, Edinburgh, London, New York, 85.
- [10] Elizabeth, J.S. (2015) Low Dose Human Intravenous Immunoglobulin, with Contraception Reversal, Omission of Water Foods without Scales, Gills, Consumption of Essential Fatty Acids Rich Diet, Reverted Neuromyelitis Optica, Systemic Lupus Erythematosus, Progressive Systemic Sclerosis, Demyelination Encephalopathy. *Journal of Dental and Medical Sciences*, **14**, 48-49.
- [11] Varga, J. (2012) Progressive Systemic Sclerosis. In: *Harrison's Principles of Internal Medicine*, 18th Edition, Volume 2, McGraw Hill, New York, 2757-2758.
- [12] Paton, N.I. (1999) Outbreak of Nipah Virus in Abattoir Workers, in Singapore. *The Lancet*, **354**, 1253-1256. [https://doi.org/10.1016/S0140-6736\(99\)04379-2](https://doi.org/10.1016/S0140-6736(99)04379-2)
- [13] Chaudhuri, A. (2002) PGE Kennedy: Diagnosis and Treatment of Viral Encephalitis. *Postgraduate Medical Journal*, **78**, 575. <https://doi.org/10.1136/pmj.78.924.575>
- [14] Elizabeth, J.S. (2014) Global Hypoxia, Global Warming, Global Recession, Consequent to Rising Environmental Oestrogen, Equating with Aborted Blood, Contraceptive Menstrual Blood Pollution, Depleting Ozone. *International Journal of Scientific Research Publications*, **4**, 1-7.
- [15] Elizabeth, J.S. (2014) Increased Prevalence of Dermographism, Filariasis, Mosquito Borne Diseases, and Rising Environmental Oestrogen, Equating with Aborted Blood, Contraceptive Menstrual Blood Pollution. *International Journal of Scientific Research and Engineering Studies*, **1**, 5-9.
- [16] Elizabeth, J.S. (2014) Increased Prevalence of Solar Keratoses, Infectious Diseases and Rising Environmental Oestrogen, Equating with Aborted Blood, Contraceptive Menstrual Blood Pollution, with Consequent Ozone Depletion. *IOSR Journal of Environmental Science, Toxicology, and Food Technology*, **8**, 74-80. <https://doi.org/10.9790/2402-08917480>
- [17] Elizabeth, J.S. (2014) Contraception Reversal-Medical Miracle, Decline in Diseases. *IOSR Journal of Dental and Medical Sciences*, **13**, 93-102.
- [18] Elizabeth, J.S. (2014) Autoimmunity and Fragmented Germ Cells. *IOSR Journal of Dental and Medical Sciences*, **13**, 74-80.