

Accuracy and Utility of Vessel Analysis Using Non-Contrast CT for Planning Endovascular Aortic Repair

Midori Komita-Moriya¹, Yukihiisa Ogawa², Akiyuki Kotoku¹, Shintaro Nawata¹, Kenji Kuramochi³, Yasuyoshi Ogawa³, Kiyoshi Chiba⁴, Hiroshi Nishimaki⁴, Hidefumi Mimura¹

¹Department of Radiology, St. Marianna University School of Medicine, Kanagawa, Japan

²Department of Radiology, Tokai University School of Medicine Hachioji Hospital, Tokyo, Japan

³Radiological Technology, St. Marianna University School of Medicine, Kanagawa, Japan

⁴Department of Cardiovascular Surgery, St. Marianna University School of Medicine, Kanagawa, Japan

Email: ogawa.yukihiisa.r@tokai.ac.jp

How to cite this paper: Komita-Moriya, M., Ogawa, Y., Kotoku, A., Nawata, S., Kuramochi, K., Ogawa, Y., Chiba, K., Nishimaki, H. and Mimura, H. (2024) Accuracy and Utility of Vessel Analysis Using Non-Contrast CT For Planning Endovascular Aortic Repair. *Open Journal of Medical Imaging*, 14, 96-105.

<https://doi.org/10.4236/ojmi.2024.143010>

Received: August 1, 2024

Accepted: August 25, 2024

Published: August 28, 2024

Copyright © 2024 by author(s) and Scientific Research Publishing Inc. This work is licensed under the Creative Commons Attribution International License (CC BY 4.0).

<http://creativecommons.org/licenses/by/4.0/>



Open Access

Abstract

Objectives: This study aimed to determine whether errors in vascular measurements would affect device selection in endovascular aortic repair (EVAR) by comparing measurements obtained using non-contrast computed tomography (NCT) with those obtained using contrast-enhanced CT (CECT). **Materials and Methods:** This single-center, retrospective study included 25 patients who underwent EVAR for abdominal aortic aneurysm at our institution. A 1-mm horizontal cross-sectional slice of NCT and CECT from each patient was retrospectively reviewed. The area from the abdominal aorta to the common iliac artery was divided into four zones. A centerline was created using the NCT by manually plotting the center points. Subsequently, the centerlines were automatically extracted and manually corrected during the arterial phase of CECT. The diameter and length of each zone were measured for each modality. The mean diameters and lengths of the target vessels were compared between NCT and CECT. **Results:** The measurements obtained using both methods were reproducible and demonstrated good agreement. The mean differences in vessel length and diameter measurements for each segment between NCT and CECT were not statistically significant, indicating good consistency. **Conclusion:** NCT may be useful for preoperative EVAR evaluation in patients with renal dysfunction or allergies to contrast agents.

Keywords

Non-Contrast CT, Vessel Analysis, EVAR, Contrast-Enhanced CT, Abdominal Aortic Aneurysm

1. Introduction

Endovascular aortic repair (EVAR) is less invasive than open surgery and yields excellent early results for abdominal aortic aneurysm (AAA) [1]-[3]. Therefore, an increasing number of patients are undergoing endovascular aortic repair (EVAR), which has become an established standard of care along with open surgery. In addition to morphology, information regarding the vessel diameter and length, which are the landing sites at both ends of the aortic aneurysm, is necessary to determine whether EVAR is indicated and to select the device. Although vascular analysis using contrast-enhanced computed tomography (CECT) is routinely performed, most patients undergoing treatment are elderly and often opt out of EVAR because of renal dysfunction associated with comorbidities or allergies to contrast media. A previous study reported that 15% of the patients who underwent EVAR had renal dysfunction [4]. As of 2021, approximately 350,000 Japanese patients were undergoing dialysis [5]. Substituting non-contrast CT (NCT) for preoperative vascular analysis would further EVAR indications. Moreover, replacing CECT with NCT reduces radiation exposure. Therefore, this study aimed to determine whether errors in vascular measurements would influence device selection in EVAR by comparing the measurements obtained using NCT with those obtained using CECT.

2. Materials and Methods

This was a single-center, retrospective study. Among the 42 patients who underwent EVAR for AAA at our institution between May 2016 and June 2019, 25 with 1-mm horizontal cross-sectional slices of NCT and CECT were retrospectively reviewed. The exclusion criteria were as follows: Hostile neck anatomy defined as 1) neck length < 10 mm, 2) bulging > 3 mm, 3) > 2 mm reverse taper within 1 cm below the renal arteries, and 4) neck thrombus \geq 50% of circumference and isolated or concomitant common iliac artery aneurysms. Anatomical instructions for use (IFU) were defined as 1) proximal neck length \geq 15 mm, 2) proximal neck angulation \leq 60° and 3) common iliac artery length \geq 10 mm. The area from the abdominal aorta to the common iliac artery was divided into four zones: Zone 1 (Z1), immediately below the lower renal artery to the proximal end of the AAA; Zone 2 (Z2), the proximal end of the AAA to the terminal aorta; Zone 3 (Z3), the right common iliac artery; and Zone 4 (Z4), the left common iliac artery. The long and short diameters and the length of the vessel were measured using Ziostation2 version 2.4.3.3 (Ziosoft Inc., Tokyo, Japan). (Figure 1)

This study was approved by the Ethics Review Committee of St. Marianna University School of Medicine (Approval No. 4927), and it complied with the Declaration of Helsinki's use of human data.

Twenty-five patients who underwent EVAR were retrospectively evaluated. The area from the abdominal aorta to the common iliac artery was divided into four zones: Zone 1, immediately below the lower renal artery to the proximal

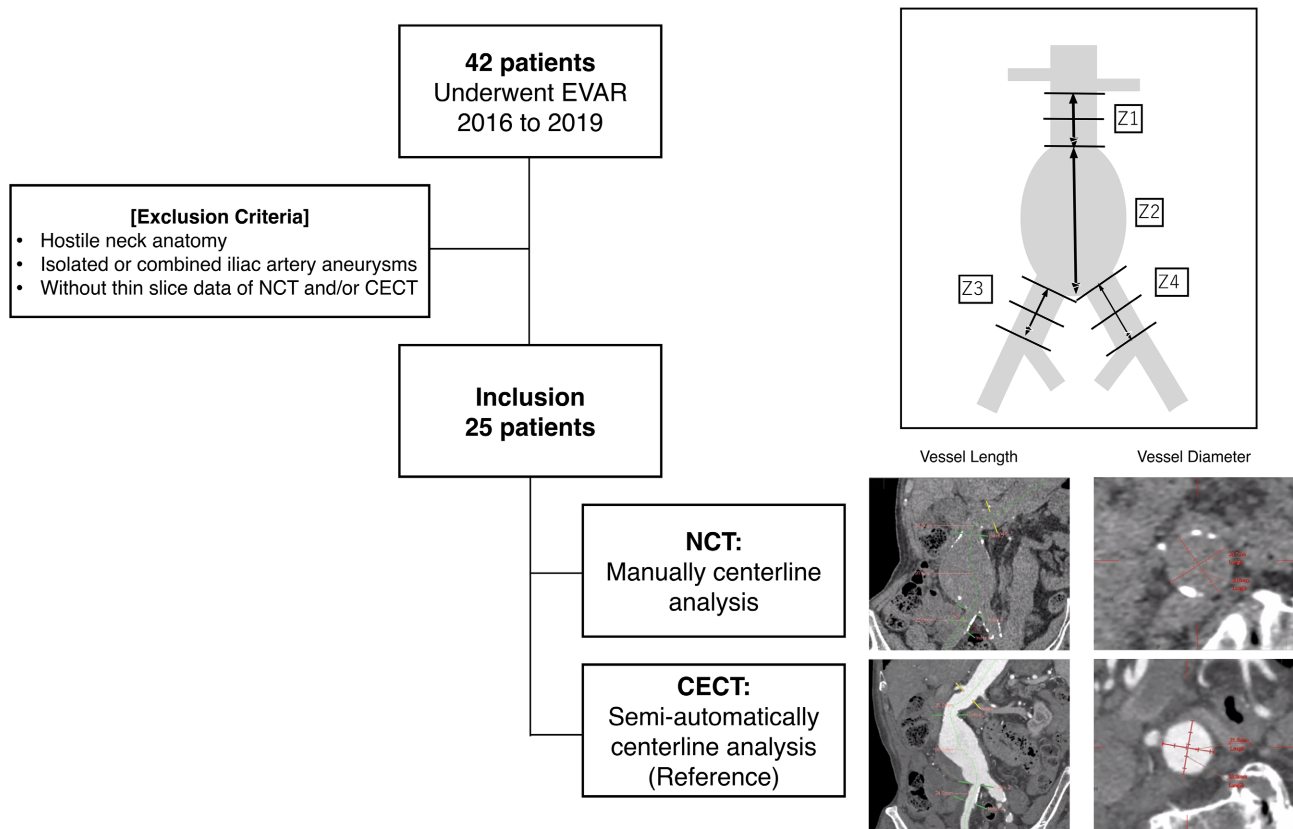


Figure 1. Flow diagram of patient inclusion and exclusion.

end of the AAA; Zone 2, the proximal end of the AAA to the terminal aorta; Zone 3, the right common iliac artery; and Zone 4, the left common iliac artery.

Using ZioStation, points were manually plotted every 5 mm on the abdominal aorta in the NCT images, whereas the centerlines were automatically extracted and subsequently manually corrected in the CECT images. After creating the centerline, the length of each vessel segment and diameters of the proximal, middle, and distal sections were manually measured.

EVAR, endovascular aortic repair; NCT, non-contrast computed tomography; CECT, contrast-enhanced computed tomography; AAA, abdominal aortic aneurysm

2.1. Measurements

Centerline was created using NCT by manually plotting the center points of the vessels at 5-mm intervals within the diaphragmatic aorta and the end of the bilateral common iliac artery. Subsequently, a cardiovascular radiologist with 9 years of experience manually corrected the automatically extracted centerlines in the CECT arterial phase. The measured vessel lengths per segment and vessel diameters on CECT were used as references. The long and short diameters at the proximal, middle, and distal points in Z1, Z3, and Z4 and the length of the vessels in each zone were measured. The mean vessel diameter was calculated as the average of the long and short diameters $(\text{long} + \text{short diameter})/2$ on the cross-sectional

images. The same raters (a radiologist with 4 years of experience and a cardiovascular radiologist with 9 years of experience) obtained the measurements twice, at an interval of at least 1 month.

2.2. Evaluation Items and Statistical Analyses

The statistical software used was JMP (version 14.2; SAS Institute Inc., Cary, North, USA). The intraclass correlation coefficient (ICC) (1, 1) was used to evaluate the intraclass reliability of the measurements. ICC reliability assessments were categorized as follows: 0.0 - 0.20, slight; 0.21 - 0.40, fair; 0.41 - 0.60, moderate; 0.61 - 0.80, substantial; and 0.81 - 1.00, almost perfect. The mean diameter and length of the target vessels obtained from NCT were compared with those obtained using the Bland-Altman method.

3. Results

Of the 25 patients, 80% were male, and the average age was 76.7 years, with an average body mass index of 22.4. The mean AAA diameter was 59 ± 11 mm. Three patients had a proximal neck angle of $>60^\circ$, accounting for 12% of the total patients considered outside the IFU (Table). There were no cases with neck thrombus $\geq 50\%$ of circumference because they were excluded from EVAR eligibility when determining the treatment policy.

Verification of reference (CECT reproducibility): intraclass correlation coefficient (ICC) (1, 1).

The ICC of the reference showed good agreement (0.98 - 0.99) for vessel length and good agreement (0.88 - 0.95) for vessel diameter.

Verification of the reproducibility of NCT: ICC (1, 1).

The ICC of the reference showed good agreement (0.87 - 0.98) for vessel length. The vessel diameter showed good agreement (0.82 - 0.92).

Table 1. Patient demographics and lesion characteristics.

Patient number	25
Male (%)	20 (80)
BMI (%)	22.4 ± 4.5
Age (year)	76.7 ± 10
AAA diameter (mm)	59 ± 11
IFU violation (%)	3 (12)
PN length < 15 mm	0
PN angulation > 60°	3
Right CIA length < 10 mm	0
Left CIA length < 10 mm	0

BMI, body mass index; AAA, abdominal aortic aneurysm; IFU, instructions for use; PN, proximal neck; CIA, common iliac artery.

3.1. Comparison between CECT and NCT

3.1.1. Vessel Length

The mean differences in the vessel length between the CECT and NCT were -1.3 mm (95% confidence interval [95% CI] -2.9 to 0.4) with a correlation coefficient of 0.98 for Z1 (**Figure 2(a)**), 12.2 mm (95% CI, 6.8 to 17.6) with a correlation coefficient of 0.83 for Z2 (**Figure 2(b)**), 2.0 mm (95% CI, -0.2 to 4.2) with a correlation coefficient of 0.91 for Z3 (**Figure 2(c)**), and 0.2 mm (95% CI, -2.0 to 2.4) with a correlation coefficient of 0.95 for Z4 (**Figure 2(d)**). None of these differences were statistically significant, thereby demonstrating good consistency.

3.1.2. Vessel Diameter

The mean differences in the mean vessel diameter between the CECT and NCT

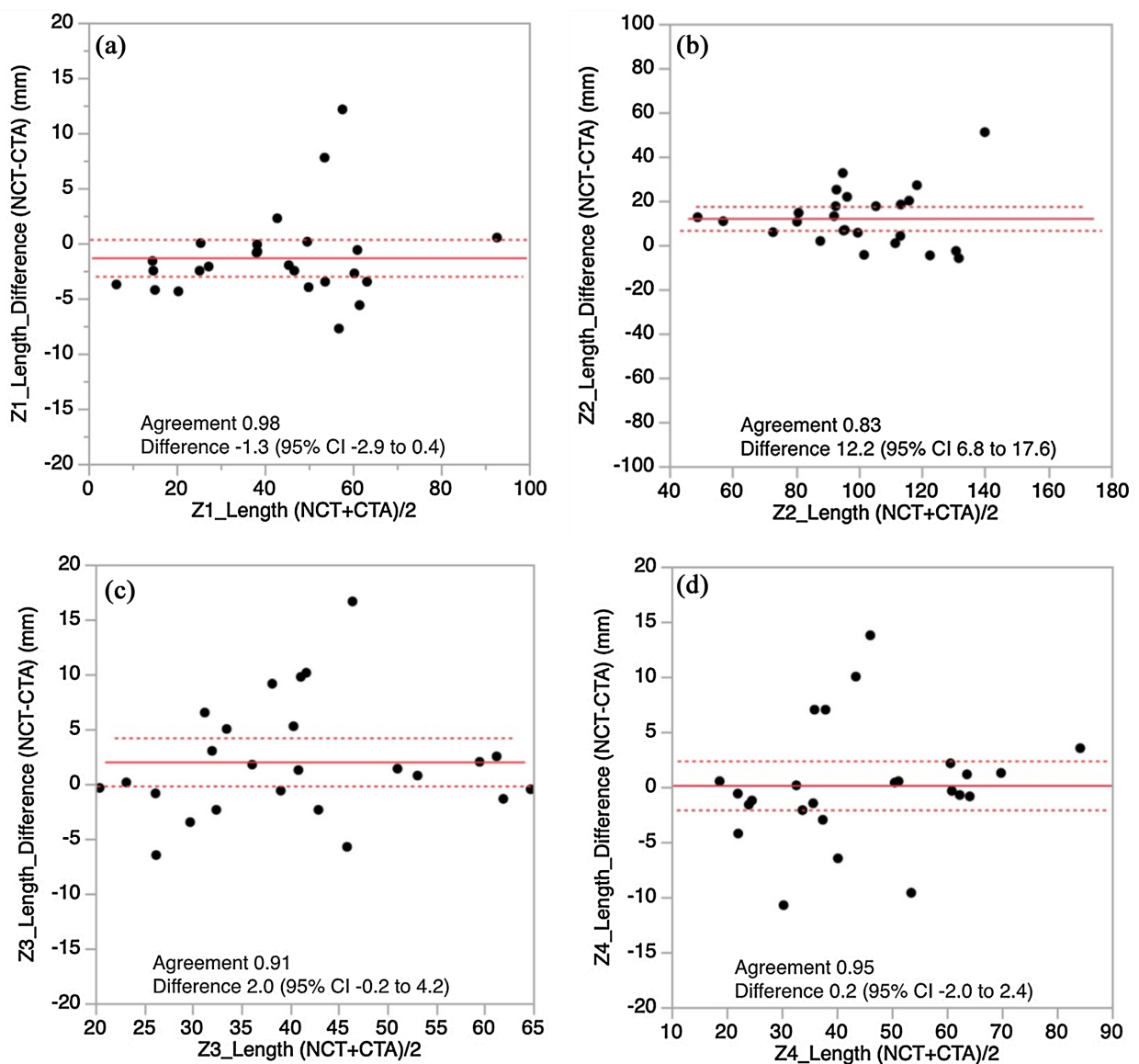


Figure 2. Mean difference in vessel length between the reference and non-contrast CT. Bland-Altman plots show no significant differences, indicating good consistency.

were 1.0 mm (95% CI, 0.7 to 1.3) for Z1 (**Figure 3(a)**) with a correlation coefficient of 0.97, 0.9 mm (95% CI, 0.6 to 1.2) for Z3 (**Figure 3(b)**) with a correlation coefficient of 0.92, and 0.6 mm (95% CI, 0.3 to 1.0) for Z4 (**Figure 3(c)**) with a correlation coefficient of 0.93. Although there were non-significant mean differences of approximately 1 mm in all segments, the correlation coefficients indicated strong correlations.

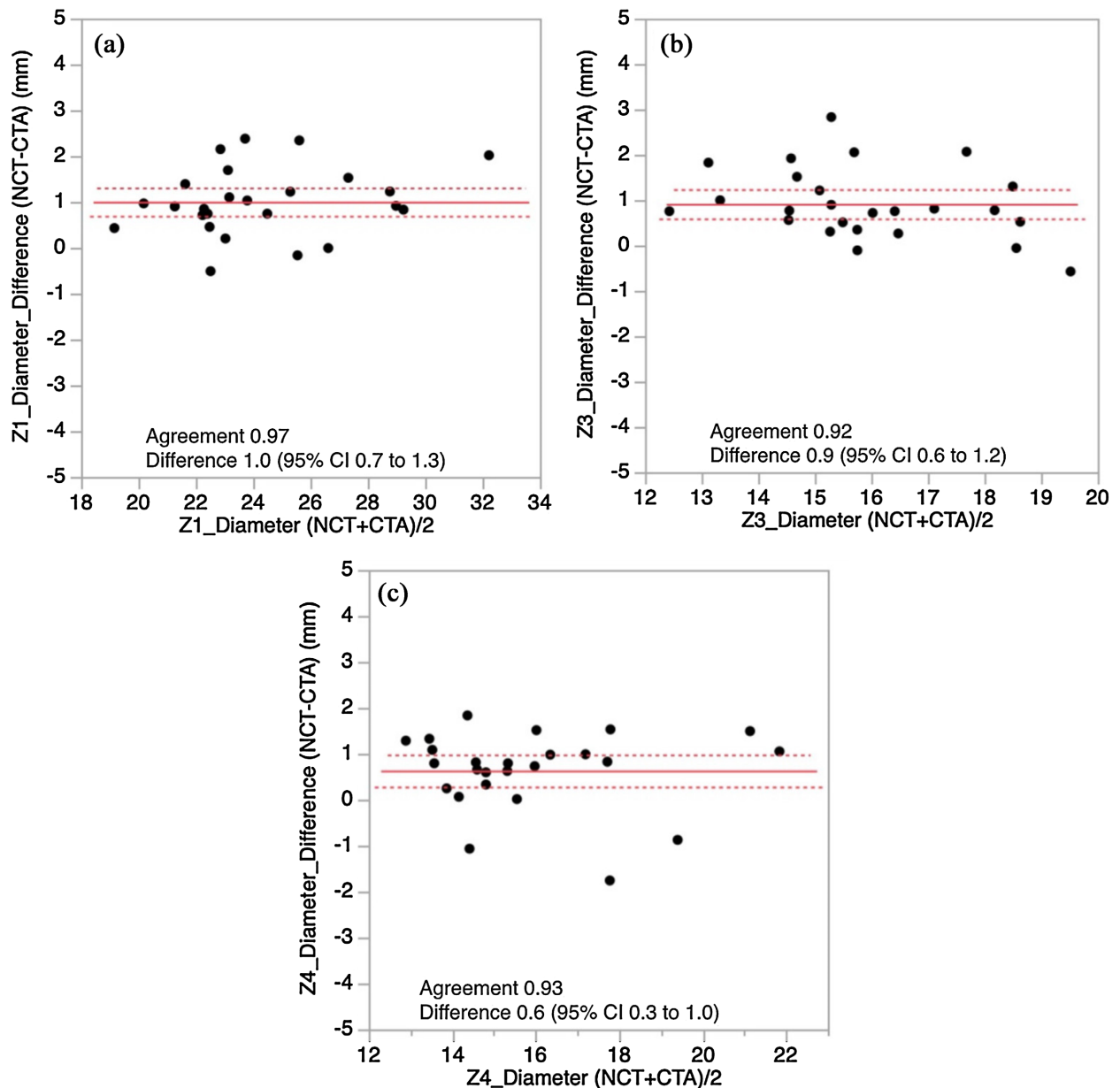


Figure 3. Mean difference in vessel diameter between the reference and non-contrast CT. Bland-Altman plots show differences of approximately 1 mm without significance, and the correlation coefficients indicate strong correlations.

4. Discussion

This is the first study to indicate that vessel measurements on NCT may facilitate the planning of EVAR in patients with renal dysfunction or allergies to con-

trast media because of the minimal margin of error.

Several guidelines recommend reducing CECT to the minimum necessary level and evaluating NCT levels using ultrasonography after EVAR surveillance [6] [7]. However, preoperative evaluation typically requires CECT to obtain accurate vessel measurements during EVAR. The results of this study are valuable because they demonstrate the possibility of using NCT for the preoperative evaluation of EVAR, which can reduce radiation exposure and the risk of acute kidney injury.

This study used the manual centerline method to measure the vessel length and diameter on NCT, whereas a semiautomatic method was used for CECT. The differences in vessel measurements between manual and semiautomated processing tools for the thoracic aorta were not significant [8]. In this context, the thoracic aorta is surrounded by the lungs, providing clear contrast, making it feasible to perform vessel measurements using NCT with minimal errors [9]. However, the difference in the aortic arch diameter at the branching vessel location was significant, making it difficult to measure the aortic diameter at these points on NCT.

Our findings showed that Z4 exhibited relatively large discrepancies between the NCT and CECT measurements despite the centerline being accurately drawn in most cases. These discrepancies were particularly notable in patients with little visceral fat, making it difficult to distinguish between the internal and external iliac arteries and the surrounding structures (Figure 4). Similar errors occurred in patients with high visceral fat, particularly when the veins were closely juxtaposed with other structures at the renal artery level or with internal and external iliac artery bifurcations. Furthermore, in cases of aneurysms extending to the distal end of the abdominal aorta, the identification of the common iliac artery bifurcation is complex, potentially contributing to measurement errors.

In addition, anatomical characteristics such as large diameter, tortuosity, and distortion may also affect measurement errors. Factors such as defining the central axis and the degree of vessel wall thickness or calcification may lead to discrepancies between NCT and CECT measurements. However, despite these variations, the overall consistency remains satisfactory, making a vascular length assessment before EVAR because the device length can be adjusted during the EVAR procedure. Moreover, the exact precision in preoperative evaluations does not significantly influence device selection.

Regarding the measurement of the vessel diameter, measurement errors remained within ≤ 2 mm in the 95% CI. These errors have a minimal effect on the selection of stent graft devices because each device has a tolerance diameter range. Furthermore, for stent grafts based on the outer vessel diameter, NCT measurements may provide more suitable values, making NCT measurements acceptable for preoperative device selection in EVAR.

In a previous report, successful vascular treatments were performed in six patients with aortic aneurysms (five cases of AAA and one case of TAA) without using contrast agents preoperatively and during the procedures [10]. This

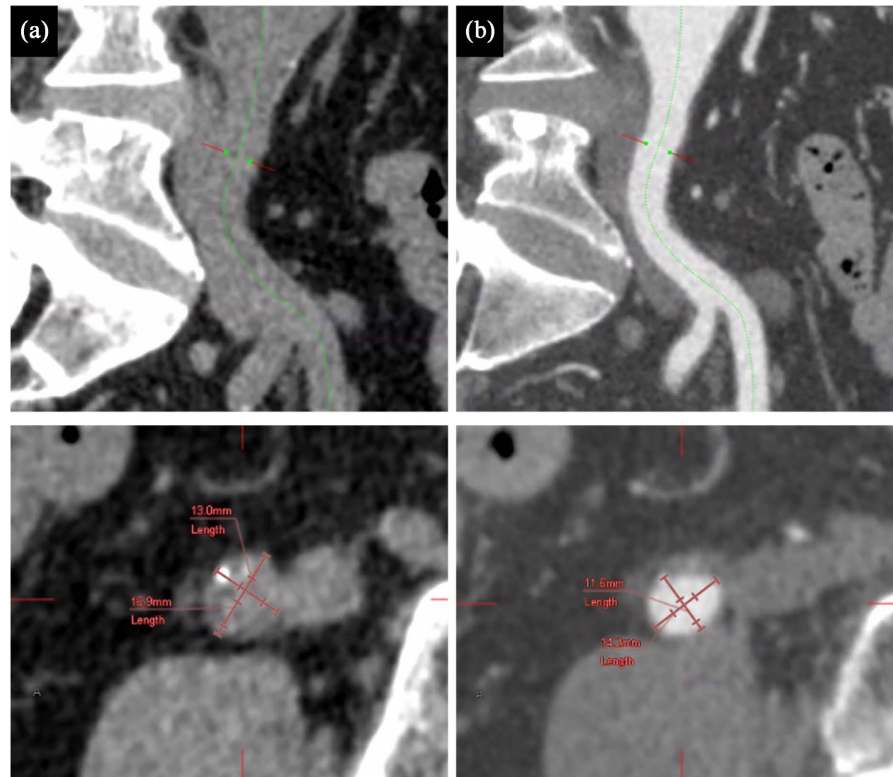


Figure 4. Cause of measurement errors. In non-contrast computed tomography (CT) scans (a), distinguishing the internal and external iliac arteries from the surrounding structures may pose challenges, particularly in cases with minimal visceral fat, compared with contrast-enhanced CT scans (b).

validation study aimed at preventing contrast-induced nephropathy. In this study, NCT was performed preoperatively and CT values were artificially enhanced based on the NCT images to conduct preoperative evaluations for EVAR. This indicates that preoperative assessment of EVAR can be safely performed using NCT. However, no studies beyond a single-case report have verified the efficacy of NCT in pre-EVAR assessment. Therefore, this study is significant because it establishes the feasibility of using NCT to plan EVAR in patients with AAAs.

A recent study demonstrated the presence of AAA by generating a virtual CECT from NCT images using a generative adversarial network, which is a type of artificial intelligence [11]-[13]. This study validated an artificial intelligence-based method for detecting AAA using vessel diameters. In the future, it would be beneficial to develop software capable of identifying AAA and measuring vessel diameter/length by performing segmentation in each segment of the NCT. For Z1 and Z2, good measurement results were obtained for both vessel diameter and length, and the main device selection was not significantly affected. However, for Z3 and Z4, there were errors in both measurements; however, these could be adjusted during the procedure. Therefore, good measurements are generally obtained for the vessel length, and the usefulness of NCT measurements for device selection can be expected.

This study had some limitations. First, it was a retrospective study with a small number of patients. Second, this study did not evaluate the access route as a specific parameter, as it can be repaired with covered stents in cases of vessel injury. Using NCT alone may result in insufficient assessment of the mural thrombus, posing a risk of distal embolization during EVAR. Therefore, NCT should ideally be complemented with non-contrast magnetic resonance angiography and vascular ultrasonography. A single rater performed all the measurements in this study. Ideally, multiple raters should obtain measurements, and comparisons among the results should be performed. This study only involved a limited number of cases; hence, additional case accumulation and evaluation are required to fully assess the utility of NCT in pre-EVAR evaluation.

5. Conclusion

NCT may be useful for preoperative evaluation in patients with renal dysfunction or allergies to contrast agents.

Acknowledgments

We thank Editage (<https://www.editage.jp>) for English language editing services.

Conflicts of Interest

The authors declare no conflicts of interest regarding the publication of this paper.

References

- [1] Prinssen, M., Verhoeven, E.L.G., Buth, J., Cuypers, P.W.M., van Sambeek, M.R.H.M., Balm, R., *et al.* (2004) A Randomized Trial Comparing Conventional and Endovascular Repair of Abdominal Aortic Aneurysms. *New England Journal of Medicine*, **351**, 1607-1618. <https://doi.org/10.1056/nejmoa042002>
- [2] Lederle, F.A. (2009) Outcomes Following Endovascular vs Open Repair of Abdominal Aortic Aneurysms Randomized Trial. *JAMA*, **302**, 1535-1542. <https://doi.org/10.1001/jama.2009.1426>
- [3] Lal, B.K., Zhou, W., Li, Z., Kyriakides, T., Matsumura, J., Lederle, F.A., *et al.* (2015) Predictors and Outcomes of Endoleaks in the Veterans Affairs Open versus Endovascular Repair (OVER) Trial of Abdominal Aortic Aneurysms. *Journal of Vascular Surgery*, **62**, 1394-1404. <https://doi.org/10.1016/j.jvs.2015.02.003>
- [4] Japanese Committee for Stentgraft Management (2013) Therapeutic Results. <http://stentgraft.jp/pro/en/result/>
- [5] JSDT Renal Data Registry (2022) 2021 Annual Dialysis Data Report, JSDT Renal Data Registry. *The Japanese Society for Dialysis Therapy*, **55**, 665-723. https://www.jstage.jst.go.jp/article/jsdt/55/12/55_665/article/-char/en
- [6] The Japanese Circulation Society, the Japanese Society for Cardiovascular Surgery, the Japanese Association for Thoracic Surgery and the Japanese Society for Vascular Surgery Joint Working Group (2023) JCS/JSCVS/JATS/JSVS 2020 Guideline on Diagnosis and Treatment of Aortic Aneurysm and Aortic Dissection.
- [7] Wanhainen, A., Verzini, F., Van Herzelee, I., Allaire, E., Bown, M., Cohnert, T., *et*

- al.* (2019) Editor's Choice—European Society for Vascular Surgery (ESVS) 2019 Clinical Practice Guidelines on the Management of Abdominal Aorto-Iliac Artery Aneurysms. *European Journal of Vascular and Endovascular Surgery*, **57**, 8-93. <https://doi.org/10.1016/j.ejvs.2018.09.020>
- [8] Entezari, P., kino, A., Honarmand, A.R., Galizia, M.S., Yang, Y., Collins, J., *et al.* (2013) Analysis of the Thoracic Aorta Using a Semi-Automated Post Processing Tool. *European Journal of Radiology*, **82**, 1558-1564. <https://doi.org/10.1016/j.ejrad.2013.03.024>
- [9] Sedghi Gamechi, Z., Bons, L.R., Giordano, M., Bos, D., Budde, R.P.J., Kofoed, K.F., *et al.* (2019) Automated 3D Segmentation and Diameter Measurement of the Thoracic Aorta on Non-Contrast Enhanced CT. *European Radiology*, **29**, 4613-4623. <https://doi.org/10.1007/s00330-018-5931-z>
- [10] Kaladji, A., Dumenil, A., Mahé, G., Castro, M., Cardon, A., Lucas, A., *et al.* (2015) Safety and Accuracy of Endovascular Aneurysm Repair without Pre-Operative and Intra-Operative Contrast Agent. *European Journal of Vascular and Endovascular Surgery*, **49**, 255-261. <https://doi.org/10.1016/j.ejvs.2014.12.003>
- [11] Hu, T., Oda, M., Hayashi, Y., Lu, Z., Kumamaru, K.K., Akashi, T., *et al.* (2021) Aorta-Aware GAN for Non-Contrast to Artery Contrast CT Translation and Its Application to Abdominal Aortic Aneurysm Detection. *International Journal of Computer Assisted Radiology and Surgery*, **17**, 97-105. <https://doi.org/10.1007/s11548-021-02492-0>
- [12] Lareyre, F., Chaudhuri, A., Flory, V., Augène, E., Adam, C., Carrier, M., *et al.* (2022) Automatic Measurement of Maximal Diameter of Abdominal Aortic Aneurysm on Computed Tomography Angiography Using Artificial Intelligence. *Annals of Vascular Surgery*, **83**, 202-211. <https://doi.org/10.1016/j.avsg.2021.12.008>
- [13] Lareyre, F., Adam, C. and Raffort, J. (2022) Automatic Measurement of Abdominal Aortic Aneurysm Maximum Diameter Using Artificial Intelligence. *European Journal of Vascular and Endovascular Surgery*, **63**, 525. <https://doi.org/10.1016/j.ejvs.2021.10.053>